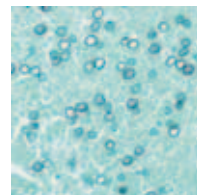


# Guide to Special Stains



---

## Guide to Special Stains

### Editor

Sonja Wulff

DakoCytomation ■ Fort Collins, Colorado, USA

### Technical Advisor

Laurie Hafer, PhD

DakoCytomation ■ Cambridge, Massachusetts, USA

### Contributors

Mary Cheles, MPH, HTL, DLM (ASCP)

DakoCytomation ■ Carpinteria, California, USA

Rick Couture, BS, HTL (ASCP)

DakoCytomation ■ Cambridge, Massachusetts, USA

Jamie M. Holliday, HT (ASCP)

DakoCytomation ■ Carpinteria, California, USA

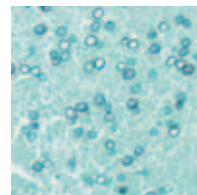
Susie Smith, BS, HTL (ASCP)

DakoCytomation ■ Cambridge, Massachusetts, USA

David A. Stanforth, BS

DakoCytomation ■ Carpinteria, California, USA





---

## Table of Contents

### Introduction to Special Stains

Historical Perspective **1**; Clinical Relevance **2**

### The Biology of Special Stains

The Cell **5**; Tissue **6**; Pathogens **8**

### The Chemistry of Special Stains

Basic Chemistry **14**; Principles Of Staining **15**

### Fixation and Tissue Processing

Fixation **17**; Specimen Processing **21**

### Staining Methods: Nucleus and Cytoplasm

Hematoxylin and Eosin **24**; Nucleic Acids **29**; Polychromatic Stains **31**

### Staining Methods: Connective Tissue, Muscle Fibers and Lipids

Connective Tissue **34**; Reticular Fibers **35**; Basement Membranes **36**; Elastic Fibers **38**; Mast Cells **39**; Muscle **41**; Trichrome Stains **41**; PTAH **44**; Modified Russel-Movat Pentachrome **45**; Lipids **46**

### Staining Methods: Carbohydrates and Amyloid

Carbohydrates **48**; Amyloid **48**; Periodic Acid-Schiff (PAS) **49**; PAS with Diastase **51**; Mucicarmine **52**; Alcian Blue **53**; Alcian Blue/PAS **55**; Colloidal Iron **56**; Congo Red **57**

### Staining Methods: Microorganisms

Bacteria **60**; Fungi **61**; Protozoans **61**; Gram Stain **62**; Acid-Fast Bacteria Stain **63**; Grocott's Methenamine Silver Stain **64**; Warthin-Starry Stain **65**; Alcian Yellow/Toluidine Blue Stain **66**; Giemsa Stain **68**; Periodic Acid-Schiff-Green Stain **69**

### Staining Methods: Pigments and Minerals

Melanin **71**; Hemosiderin **73**; Lipofuscin **74**; Urates **75**; Bile **76**; Calcium **77**; Copper **78**

### Staining Methods: Nervous System

Cresyl Violet Stain **80**; Bielschowsky Method **81**; Glial Cells **82**; Myelin **84**

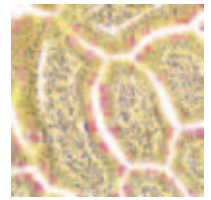
### Automation of Special Stains

Overview **86**; Advantages **86**; Considerations **87**

### Glossary **88**

### Index **90**





---

## Introduction to Special Stains

Sonja Wulff

Thousands of years ago, diagnosing and treating a patient's condition was much simpler. Ancient Egyptians blamed disease on demons, Greeks and Romans pointed to "humoral anomalies," and both looked to theological practices for healing. Today, the medical community knows so much more about the root of disease. In many cases, researchers have pinpointed causes to the molecular level, identifying specific genetic mutations and gene expression patterns linked to a particular disease, and physicians are starting to use this knowledge to match a patient's genetic profile with the most appropriate therapy. Though molecular techniques have become increasingly important in this sophisticated approach to diagnosis, pathologists and histotechnologists still require an extensive arsenal of diagnostic tools so that they can provide a complete picture of a patient's disease. Certainly, immunohistochemistry and flow cytometry will continue to play a key role, as will special staining techniques.

Special stains belong to a diverse family of slide-based stains that rely on basic chemical reactions for microscopic visualization and general identification of various tissues, structures, cells, organelles, carbohydrates, minerals and microorganisms. Introduced to all college biology students through the simple bacterial test known as the Gram stain, special stains use both science and art to provide valuable and cost-effective information for the pathology laboratory.

### Historical Perspective

The story of special stains begins several centuries ago in the early laboratories and workshops of physicians, chemists, botanists and businessmen who were just beginning to explore the world of cells and microorganisms. These histology pioneers dabbled with household goods, such as soap for embedding and wine for staining, to study diverse specimens under crude microscopes.

These early efforts enabled today's widespread use of basic staining mechanisms for morphologic evaluation. Initial protocols were limited to coloring the cell's nucleus and cytoplasm. However, as morphologic evaluation became the most important tool used by pathologists to guide patient treatment, physicians and scientists developed numerous staining procedures that now include a vast array of tinctoral stains. Today, these stains augment tissue morphology, demonstrate important cellular components, aid in the evaluation of disease states, and identify pathogenic organisms.

## Clinical Relevance

Special stains remain important tools for many pathologists, providing a powerful complement to immunohistochemistry, flow cytometry, in situ hybridization and other diagnostic technologies that ultimately define a patient's medical profile. Many special stains are key to detecting and identifying pathogens (Table 1), while others play an important role in diagnosing and monitoring cancer. Mucicarmine stains (Figure 1A), for instance, demonstrate a poorly differentiated adenocarcinoma, Giemsa stains are useful in leukemia classification, and elastic stains (Figure 1B) gauge a tumor's degree of vascular invasion. Other clinical applications for special stains cover a wide range of diseases. Iron stains (Figure 2A) can indicate hemochromatosis or iron deficiency, the Masson's Trichrome stain (Figure 2B) demonstrates changes in collagen and muscle cells associated with cirrhosis, and the Periodic Acid-Schiff stain (Figure 2C) provides information about glycogen storage disease and lupus-associated renal disease.

Table 1. Common Stains for Identifying Microorganisms

Stain	Pathogens
Acid-Fast	<i>Mycobacterium leprae</i> , <i>Mycobacterium tuberculosis</i>
Dieterle	<i>Borrelia burgdorferi</i> , <i>Legionella pneumophila</i> , <i>Treponema pallidum</i>
Giemsa	<i>Helicobacter pylori</i> , <i>Plasmodium vivax</i> , <i>Rickettsia prowazekii</i> , <i>Rickettsia rickettsii</i> , <i>Rickettsia tsutsugamushi</i>
Gram	<i>Actinomyces israelii</i> , <i>Legionella pneumophila</i> , <i>Neisseria gonorrhoeae</i> , <i>Neisseria meningitidis</i> , <i>Nocardia asteroides</i>
Grocott's Methenamine Silver (GMS)	<i>Aspergillus fumigatus</i> , <i>Blastomyces dermatitidis</i> , <i>Candida albicans</i> , <i>Coccidioides immitis</i> , <i>Cryptococcus neoformans</i> , <i>Histoplasma capsulatum</i> , <i>Nocardia asteroides</i> , <i>Pneumocystis carinii</i> , <i>Sporothrix schenckii</i>
Mayer Mucicarmine	<i>Cryptococcus neoformans</i>
Periodic Acid-Schiff (PAS)	<i>Aspergillus fumigatus</i> , <i>Blastomyces dermatitidis</i> , <i>Candida albicans</i> , <i>Coccidioides immitis</i> , <i>Cryptococcus neoformans</i> , <i>Sporothrix schenckii</i>
Steiner & Steiner	<i>Borrelia burgdorferi</i> , <i>Helicobacter pylori</i> , <i>Legionella pneumophila</i> , <i>Treponema pallidum</i>
Warthin-Starry	<i>Alipia feles</i> , <i>Bartonella henselae</i> , <i>Borrelia burgdorferi</i> , <i>Helicobacter pylori</i> , <i>Legionella pneumophila</i> , <i>Treponema pallidum</i>

## Introduction to Special Stains

---

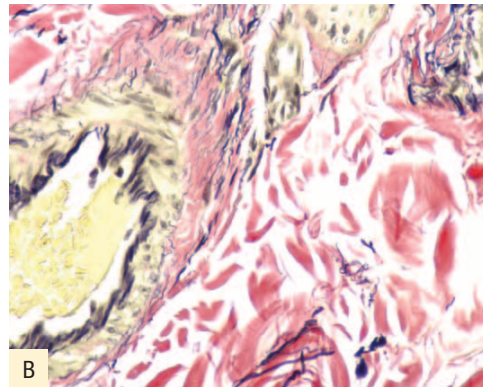
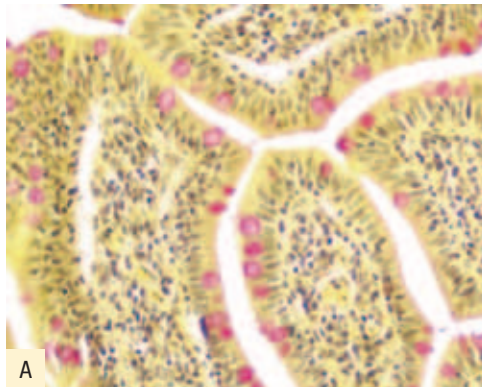
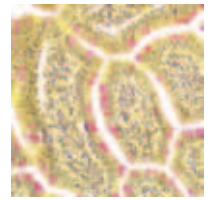


Figure 1. A) This mucicarmin stain is used for visualization of neutral epithelial mucins in small intestine. The mucins are stained rose to red, nuclei are blue/black, and other tissue elements are yellow; B) Verhoeff's elastic stain colors elastin fibers in skin black. Nuclei appear blue/black, and collagen is red. (DakoCytomation Artisan)

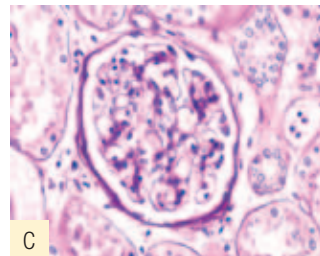
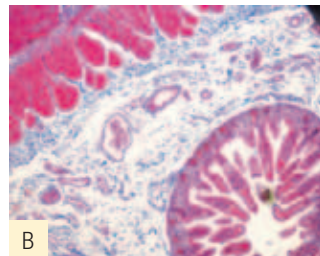
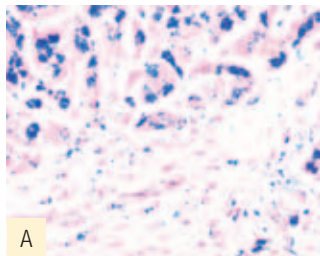


Figure 2. A) This iron stain is used for visualization of ferric iron in liver sections. Ferric deposits are stained blue, nuclei are red, and background tissue elements are pink to red; B) Masson's trichrome stain differentiates between collagen and smooth muscle in the liver, with muscle staining red, collagen blue and fibrin pink; C) This PAS stain is used for the visualization of mucopolysaccharides and glycogen in renal tissue. Mayer's hematoxylin counterstains the nuclei blue. (DakoCytomation Artisan)


### Automation

As the medical community demands greater standardization, special stain protocols have become increasingly automated. For today's histology and anatomic pathology laboratories, the result is new levels of productivity, flexibility and environmental safety. With special staining techniques remaining an integral part of any pathologic diagnosis, this technology will continue to evolve.



### References

1. Campbell NA. Biology. 3rd ed. Redwood City, CA: The Benjamin/Cummings Publishing Company, Inc.; 1993.
2. Carson FL. Histotechnology: A self-instructional text. 2nd ed. Chicago: ASCP Press; 1997.
3. Disease information. 2003; Available at: <http://www.cdc.gov/ncidod/dbmd/diseaseinfo>. Accessed October 9, 2003.
4. Luna LG. Predictions of the Decade. Histo-Logic 1980; 10th anniv. issue; 3–9.
5. Perry JJ, Staley JT. Microbiology: Dynamics and diversity. Fort Worth, TX: Saunder College Publishing; 1997.
6. Wolfe SL. Molecular and cellular biology. Belmont, CA: Wadsworth Publishing Company; 1993.



# The Biology of Special Stains

Sonja Wulff

In optimizing special staining techniques, it is important to understand the underlying biology. A basic knowledge of the cells, tissues and microorganisms involved provides insight into factors that may influence the quality of a stain or change staining characteristics. The goal of this chapter is to introduce the key biological players relevant to the performance and application of special stains.

## The Cell

The cell is the basic building block of all tissues and microorganisms and, as such, deserves attention in this chapter (Figure 1). The focus here will be on human and animals cells, which each have two major components that can be visualized easily with light microscopy — the nucleus and the cytoplasm.

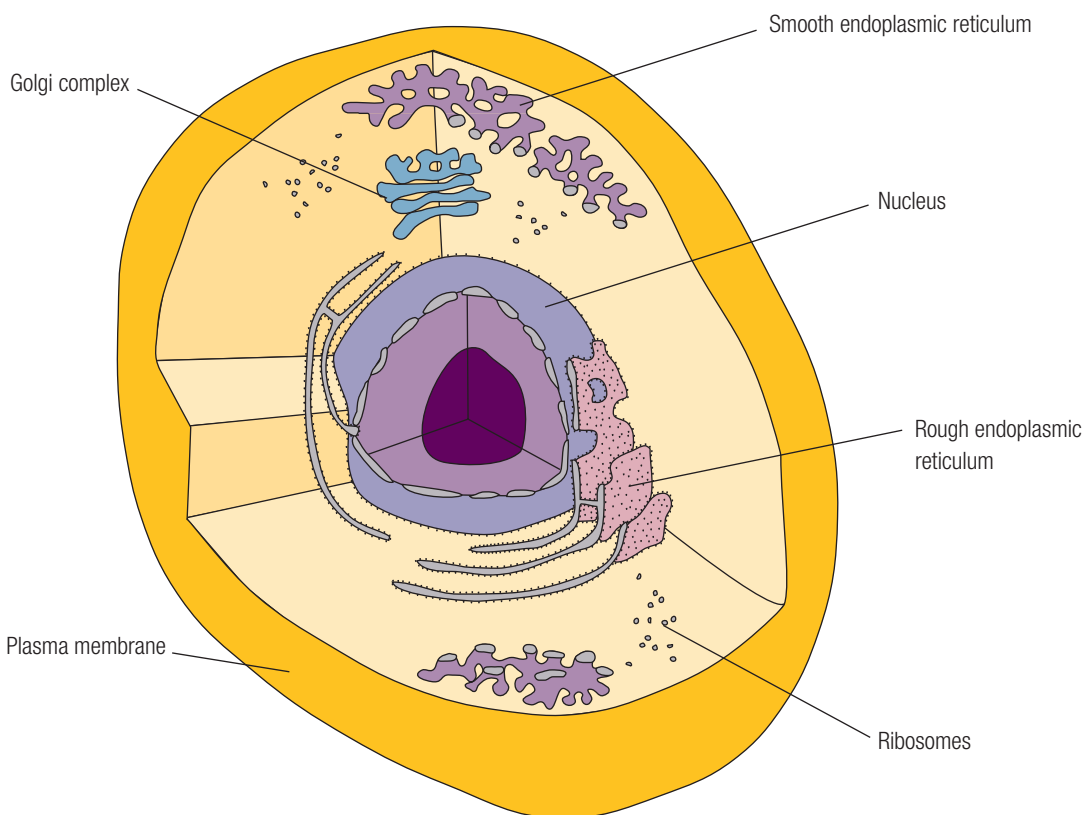


Figure 1. The Cell

### The Nucleus

The nucleus is a membrane-bound organelle that houses the cell's genetic material. Several nuclear structures have particular relevance when discussing special stains. The nuclear membrane, nucleolus and chromatin are all visible with the light microscope and may vary in appearance, depending on the state of the cell. The nuclear membrane is the structure that surrounds the nucleus and controls movement of materials between the nucleus and the cytoplasm. The nucleolus is a dense, rounded mass made up of 80–90% protein. Active cells may have multiple nucleoli. Chromatin is a complex of nucleic acids and proteins, often used to determine appropriate nuclear staining levels. Cells actively engaged in protein synthesis will exhibit only slight chromatin staining.

### The Cytoplasm

The cytoplasm is the site of most of the cell's housekeeping functions, which are carried out as directed by the nucleus. The appearance of the cytoplasm can vary greatly from cell to cell and, thus, plays a key role in distinguishing different types of cells. It also contains several common structures that provide valuable information about the cell and its activity. Ribosomes — the site of protein synthesis — stain differently based on whether they are free in the cytoplasm or attached to the endoplasmic reticulum. The endoplasmic reticulum is a series of membrane-bound channels that transport secretory products for use in the cell or for export out of the cell. The rough endoplasmic reticulum, or endoplasmic reticulum with associated ribosomes, is abundant in cells that produce materials for export out of the cell. Finally, the Golgi apparatus both performs chemical modifications on newly made proteins and packages secretory vesicles for transport to the cell surface. In very active cells, the Golgi apparatus may appear as a nuclear halo.

### Tissue

A tissue is a group of cells with a common structure and function. For histological purposes, tissues are typically classified into four main categories: epithelial tissue, connective tissue, muscle tissue and nervous tissue.

### Epithelial Tissue

Epithelial tissue occurs in sheets of tightly packed cells that cover the outside of the body and line organs and cavities within the body. The role of this tissue, known as the epithelium, is protection, secretion and absorption. The surface of the epithelium is exposed to air or fluid, while the cells at the base of the tissue are attached to a layer of extracellular material known as the basement membrane (Figure 2). The tissue is classified based on the number of cell layers and the shape of the cells on the free surface.

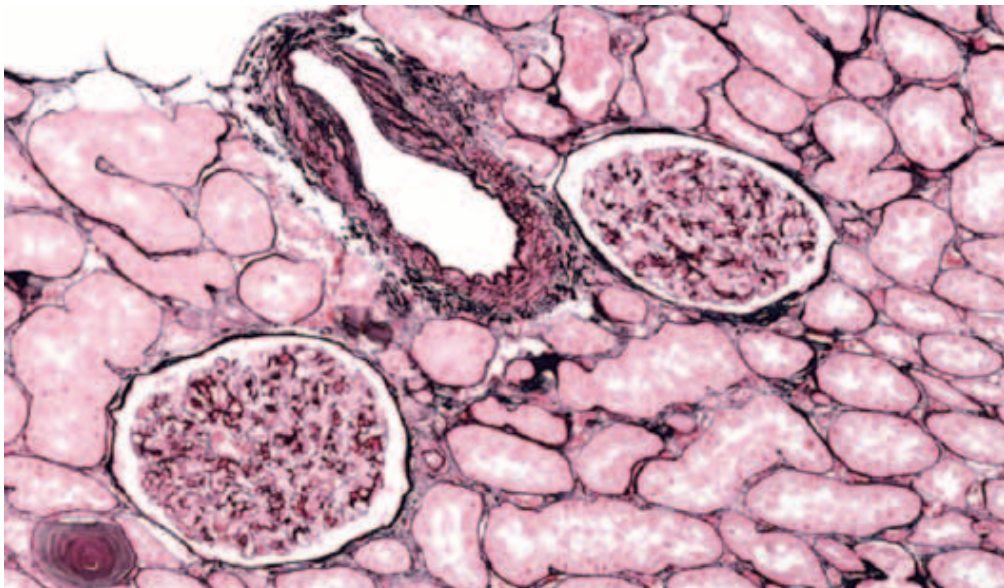



Figure 2. Jones' basement membrane stain is used for visualization of basement membranes in renal tissue. The inner basement membrane is stained black to gray, the nuclei red, collagen rose and cytoplasm and other tissue pink. (DakoCytomation Artisan)

### Connective Tissue

Connective tissue is made up of cells distributed through an extracellular matrix to bind and support other tissues. Loose connective tissue — the most widespread type of connective tissue in the body — attaches epithelial tissue to underlying tissues and holds organs in place. It includes elastic fibers (Figure 3A), reticular fibers (Figure 3B) and collagenous fibers (Figure 3C), with macrophages and fibroblasts scattered throughout. Other types of connective tissue include cartilage, blood, adipose tissue, bone and fibrous connective tissue, which is found in tendons and ligaments.

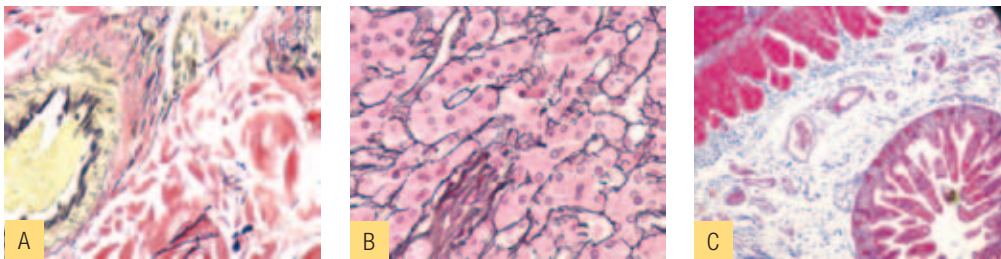


Figure 3. (A) Verhoeff's elastic stain colors elastin fibers in skin black. Nuclei appear blue/black, and collagen is red; (B) The reticulin nuclear fast red stain is used for the visualization of reticulin fibers in a liver tissue section. The reticulin fibers appear black, with all background tissue elements pink to red; (C) Masson's trichrome stain differentiates between collagen and smooth muscle in the liver, with muscle staining red, collagen blue and fibrin pink. (DakoCytomation Artisan)

### Muscle Tissue

Muscle tissue, which accounts for about two-thirds of the bulk of a well-conditioned human, contains long, contractable cells designed for movement and strength. Skeletal muscle, which is attached to bones by tendons, is responsible for most of the voluntary movements of the body. Cardiac muscle, which is striated and branched, forms the wall of the heart. Smooth muscle, which is found in the walls of most internal organs, contracts more slowly than other types of muscle but can remain contracted for a longer time (Figure 3C).

### Nervous Tissue

Nervous tissue is designed to sense stimuli and transmit signals from one part of the body to another. A nerve cell, or neuron, has a unique cellular structure with a cell body and two or more appendages, called nerve processes, which can be meters long (Figure 4).

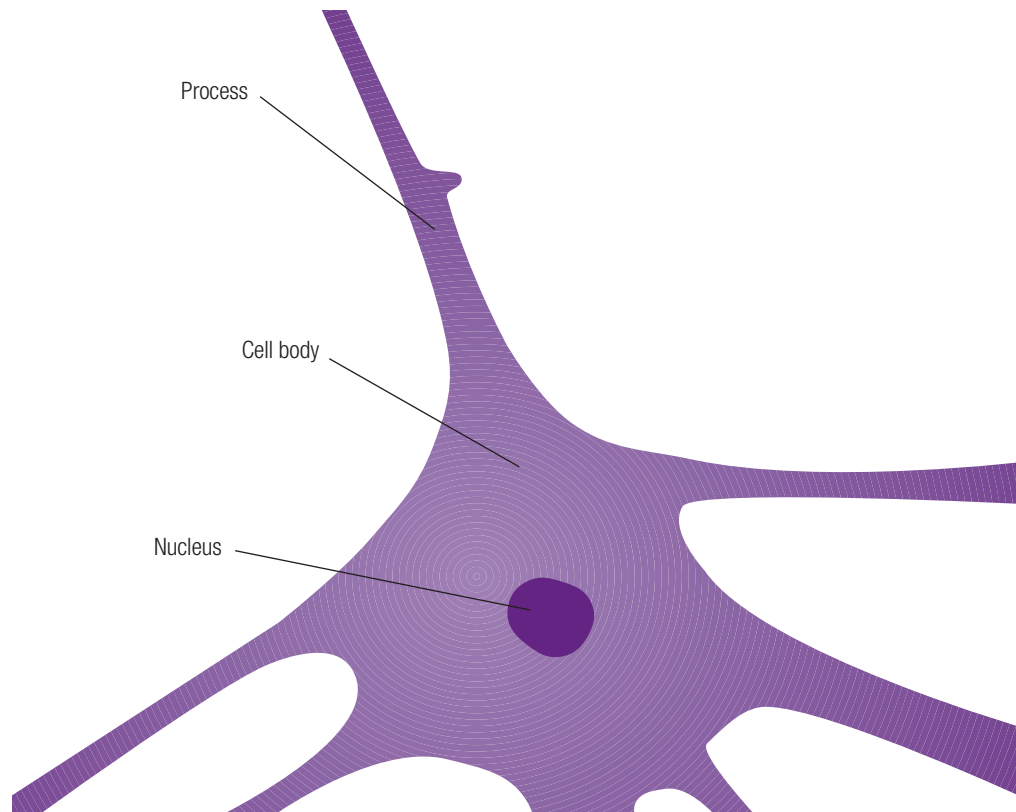



Figure 4. Nerve Cell

### Pathogens

Since the goal in performing many special stains is detection and identification of microscopic, pathogenic organisms, any basic discussion of special staining techniques



requires some knowledge of relevant pathogens. These pathogens fall into three primary classifications: bacteria, fungi and protozoans.

### Bacteria

Bacteria are tiny, single-celled organisms that range in size from 0.2  $\mu\text{m}$  to 10  $\mu\text{m}$ . They are protected by a cell wall but have no nuclear membrane enclosing their genetic material. Though the cell walls of pathogenic bacteria share a basic chemical composition — cross-linked chains of amino sugars, glucosamine and muramic acid — about 100 types of cell wall structures allow diagnostic differentiation of these organisms into major groups.

At the most basic level, bacteria can be classified as either Gram-positive or Gram-negative (Figure 5). The cell walls of Gram-positive bacteria are made up of thick, uniform layers of peptidoglycan, teichoic acids and teichuronic acids, while the cell walls of Gram-negative bacteria are more structurally complex, with much less peptidoglycan and no teichoic or teichuronic acid. Additionally, Gram-negative bacteria have a unique outer membrane containing lipids, proteins and polysaccharides. Examples of Gram-positive bacteria include *Clostridium botulinum*, *Clostridium tetani* and *Corynebacterium diphtheriae*. *Salmonella*, *Shigella dysenteriae*, *Escherichia coli* and *Pseudomonas aeruginosa* are Gram-negative bacteria.

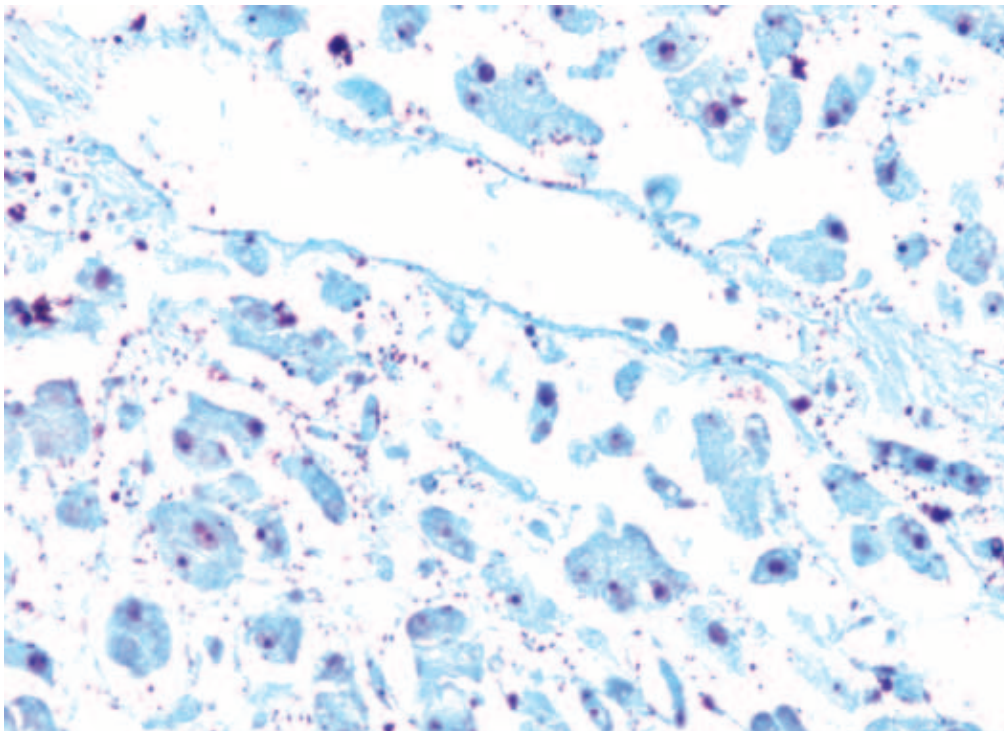


Figure 5. The modified Gram stain, performed here on placental tissue, uses crystal violet to mark the Gram-positive bacteria blue, and decolorization changes the Gram-negative bacteria red. Twort's stain imparts a blue-green background for easier visualization. (DakoCytomation Artisan)



## Special Stains

### Mycobacteria

A family of bacteria with particular diagnostic relevance is Mycobacteria. Members of this family, which include *Mycobacterium tuberculosis* and *Mycobacterium leprae*, are nonmotile rod-shaped bacteria that typically bundle together to form cordlike groups. These bacteria produce a distinctive group of waxy substances, called mycolic acids that covalently link to peptidoglycan in the bacterial cell wall. Mycolic acids make standard staining procedures difficult, but they also uniquely withstand alcohol decolorization following staining with hot carbol-fuchsin. This property, known as acid fast, is an excellent diagnostic differentiator (Figure 6).

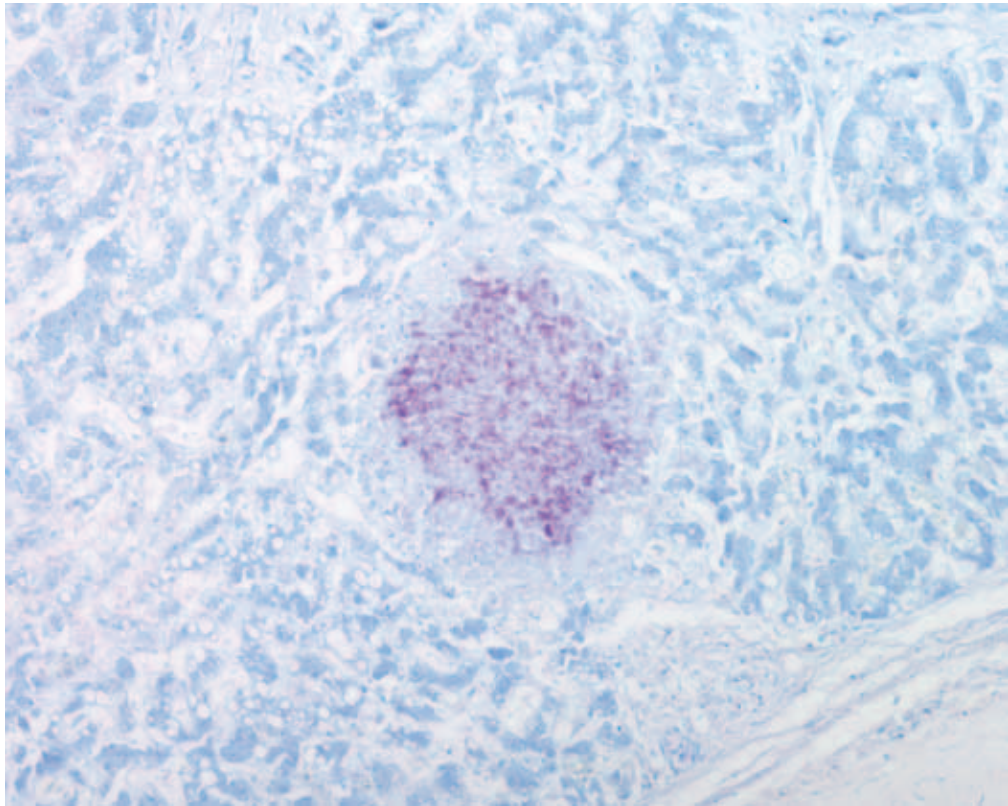


Figure 6. The acid-fast bacteria stain, performed here on lung tissue, allows visualization of bacteria belonging to the *Mycobacterium* genus. Application of carbol-fuchsin stains acid-fast bacteria fuchsia, while a methylene blue counterstain imparts a blue color to all background tissue elements. (DakoCytomation Artisan)

### Helicobacter

Another common target for special staining procedures is *Helicobacter pylori*, a spiral-shaped bacterium implicated in gastric inflammation, peptic ulcers and gastric cancer (Figure 7A). *H. pylori* produce an adhesive that allows attachment to stomach epithelial cells and a urease that provides protection from the highly acidic environment in the stomach.

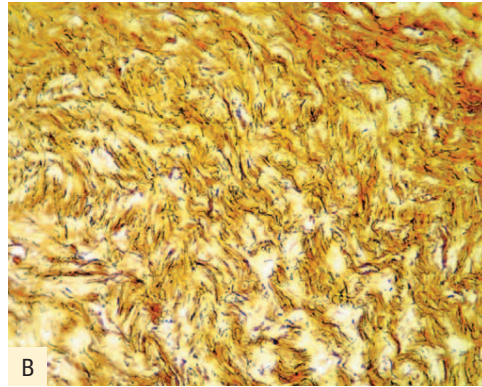
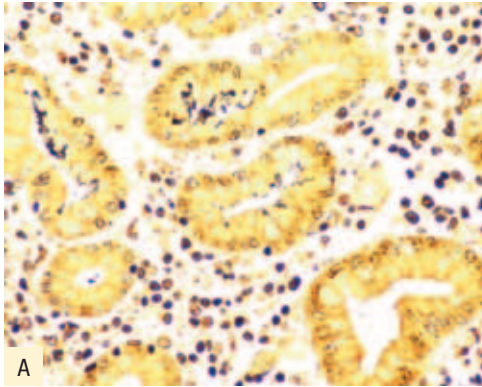



Figure 7. The Warthin-Starry stain is used for the visualization of *H. pylori* (A) and Spirochetes (B). The microorganisms appear black, while the background is pale yellow to light brown. (DakoCytomation Artisan)

### Spirochetes

Spirochetes are readily recognized by their distinct helical shape and motility (Figure 7B). Members of the genus *Treponema* live in the mouth, digestive tract, and genital areas of humans and other animals and are the causative agent of syphilis and yaws, a contagious tropical disease. Members of the genus *Borrelia* (3–20  $\mu\text{m}$ ) are the causative agents of tick-borne Lyme disease and relapsing fever. Members of the genus *Leptospira* are the causative agent of leptospirosis, which can cause kidney damage, meningitis, liver failure and respiratory distress if left untreated.

### Fungi

Fungi are primitive unicellular or multicellular plants with a distinct membrane-bound nucleus containing genetic material. They are responsible for a number of human diseases.

The most common fungal disease in humans is histoplasmosis, which is caused by the organism, *Histoplasma capsulatum*. Reproductive spores are inhaled from the soil and lodge in the lungs, sometimes creating lesions that become calcified. Three other types of fungi can cause similar respiratory diseases – *Pneumocystis carinii*, *Coccidioides immitis* and *Blastomyces dermatidis*. *P. carinii* (Figure 8) is a fungus known to cause a fatal pneumonia in immunocompromised individuals. Infection with *C. immitis* typically doesn't result in symptoms, though chronic disease can occur when spherules of the organism collect in localized pockets in the lungs. Roughly half the patients infected with *B. dermatidis* present with flu-like symptoms, and those who fail to recover can develop chronic pulmonary infection or systemic disease affecting the skin, bones and genitourinary tract.

The other major group of fungi involved in human disease is yeast. *Candida albicans* is a normal resident of the gastrointestinal tract, mouth and vaginal area, and is typically kept in check by the body's normal flora. However, in the absence of the normal flora



## Special Stains

or in immunocompromised individuals, *C. albicans* can proliferate and cause disease systemically, orally and vaginally. Another member of the yeast family, called *Cryptococcus neoformans*, can infect the lungs, though patients typically don't develop symptoms, except in the case of immunocompromised individuals.

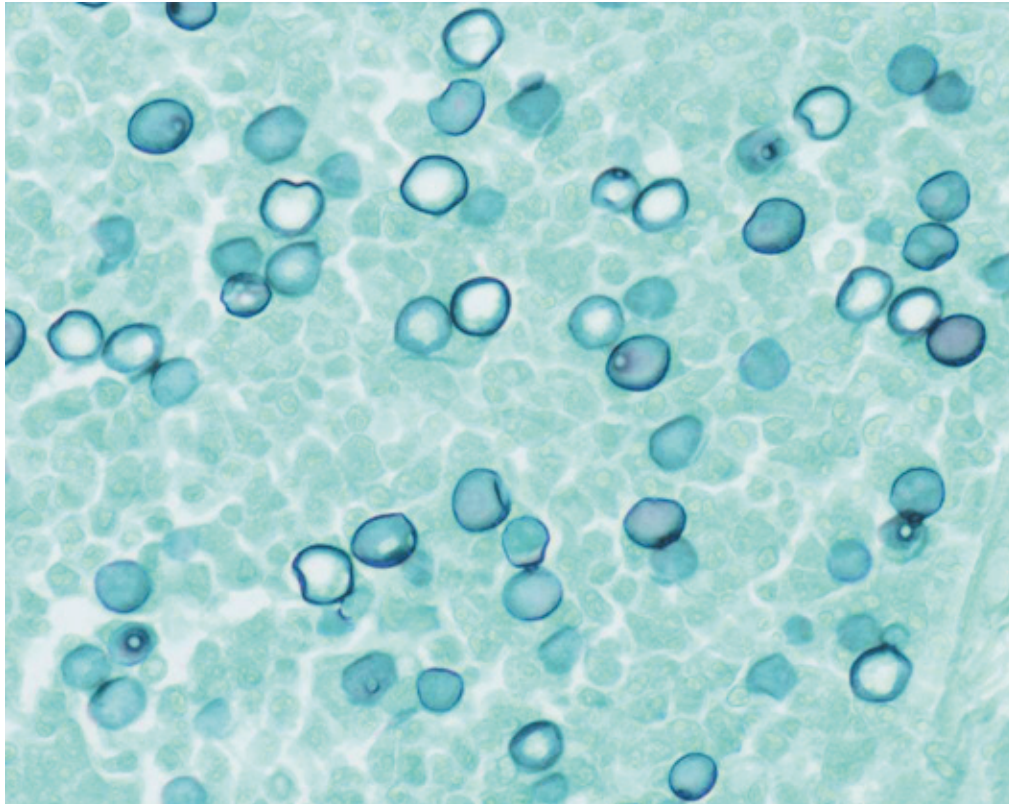



Figure 8. With the modified Grocott's methanamine silver method, *P. carinii* stains black, while other tissue elements are bluish green. (Autostainer Plus)

### Protozoans

Protozoans are single-celled organisms that lack a cell wall. This family includes Amoebae and Flagellates. Amoebae are noted for their peculiar movement in which the cell projects membrane extensions of the cytoplasm, called pseudopodia, into the environment. The cytoplasm then flows into the area of the pseudopodium. Flagellates are protozoans that move by long flagella, which resemble tails. Pathogenic members of this family include *Entamoeba histolytica*, which causes amoebic dysentery; *Naegleria fowleri*, which causes encephalitis; *Toxoplasma gondii*, which affects the central nervous system; *Trichomonas vaginalis*, a sexually transmitted protozoan that causes a vaginal infection; and *Trypanosoma gambiense*, which causes African sleeping sickness.



### References

1. Campbell NA. Biology. 3rd ed. Redwood City, CA: The Benjamin/Cummings Publishing Company, Inc.; 1993.
2. Carson FL. Histotechnology: a self-instructional text. 2nd ed. Chicago: ASCP Press; 1997.
3. Disease information. 2003; Available at: <http://www.cdc.gov/ncidod/dbmd/diseaseinfo>. Accessed October 9, 2003.
4. Perry JJ, Staley JT. Microbiology: dynamics and diversity. Fort Worth, TX: Saunder College Publishing; 1997.
5. Ross MH, Kaye GI, Pawlina W. Histology: a text and atlas. 4th ed. Philadelphia: Lippincott Williams & Wilkins; 2003.
6. Wolfe SL. Molecular and cellular biology. Belmont, CA: Wadsworth Publishing Company; 1993.

# The Chemistry of Special Stains

Sonja Wulff

At the most basic level, special staining techniques are simple chemical reactions. Visualization is not dependent on specific antibody binding or nucleic acid hybridization. Rather, special staining techniques demonstrate the presence of a particular type of tissue, cell, organelle or substance, relying on acid-base chemistry, oxidation-reduction reactions and other elementary chemical concepts. This chapter reviews these concepts and serves as an introduction to more detailed discussions of special staining techniques and technical considerations in this publication.

## Basic Chemistry

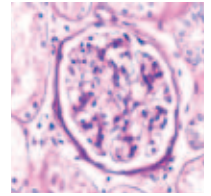
### Oxidation and Reduction

Numerous special staining techniques rely on the fundamental chemical processes of oxidation and reduction. Oxidation is a chemical reaction involving the removal of electrons from a molecule, while reduction is a chemical reaction that adds electrons. Thus, an oxidation-reduction reaction involves the transfer of electrons from one substance to another. In special staining techniques, oxidizing or reducing agents act on tissue sections, so that subsequently applied dyes or reagents can bind to or react with particular tissue elements, resulting in visualization.

### Acids, Bases, pH and Buffers

Many special staining techniques are dependent on the use of acids, bases and buffers for optimal performance. The pH of a solution is a measure of its acidity, specifically the relative concentrations of hydrogen ions ( $H^+$ ) and hydroxyl ions ( $OH^-$ ). These relative ion concentrations determine how the molecules in that solution will react. On the pH scale of 0 to 14, 7 is neutral, meaning the solution contains equal numbers of hydrogen and hydroxyl ions; less than 7 is acidic, meaning the solution contains more hydrogen than hydroxyl ions; and greater than 7 is basic, meaning the solution contains more hydroxyl than hydrogen ions. With special staining techniques, acids and bases are used either to adjust the pH of a solution prior to or during a protocol, or to facilitate an oxidation-reduction reaction.

When discussing pH, the term, acid, refers to a substance that releases hydrogen ions into solution, while the term, base, refers to a substance that releases hydroxyl ions. In histochemistry, the terms acid and base are also used in contexts independent of pH. A basic, or cationic, dye has a positively charged ion, while an acidic, or anionic, dye has a negatively charged ion. Basophilic elements, such as the nucleus, are easily stained with



basic dyes, while acidophilic elements, such as the cytoplasm, muscle and collagen, are easily stained with acidic dyes.

Buffers are solutions that are used to prevent a change in pH when acids or bases are added to the environment. The buffers used in special staining techniques can be critical to the success of a special stain.

### Principles Of Staining

For anyone with a basic biology or chemistry background, the terminology used so far in this chapter should be relatively familiar. However, additional vocabulary that is specific to histochemistry also deserves introduction and review here. Examining the typical steps from specimen acquisition to successful stain will provide useful context.

The first step in the process of preparing a specimen for staining is fixation. Fixation, or protein stabilization, preserves the specimen in a reproducible manner that most closely resembles its living state. Next, the specimen must be dehydrated, cleared and infiltrated with a substance that will allow sectioning, or cutting, of the specimen. Sectioning, or slicing the specimen into sections typically 3–5  $\mu\text{m}$ , is the final step in preparing the specimen for staining. These thin sections are placed onto glass slides, dried and then stained.

Before beginning the staining process, however, some specimens require special preparation. With some stains, the first step is application of a mordant, a reagent that links a stain or dye to a tissue element. With other stains, the first step is an oxidation-reduction reaction, which prepares the tissue for subsequent reagent or dye application.

The actual staining process involves a wide variety of dyes and reactive agents. Some dyes are specifically taken up by particular tissue elements, while other dyes stain all tissue elements but are selectively resistant to subsequent decolorizing. Other staining protocols don't involve absorption at all. Metals, for instance, can deposit on or around a tissue element of interest, in a process known as impregnation. Subsequent oxidation-reduction reactions then result in visualization. Still other protocols rely on selective oxidation and reduction of tissue elements, which in turn react with metals or dyes for visualization.

To optimize visualization and address procedural artifacts such as background, or nonspecific, staining, further steps may be necessary after staining. One common technique is called differentiation. Differentiation involves application of a chemical that removes excess stain from a tissue section, leaving only the tissue element of interest stained. Successful differentiating agents have a much higher affinity for the tissue element of interest than for the surrounding tissue. Thus, decolorization occurs first in the surrounding tissue, leaving the tissue element of interest untouched. To further enhance visualization, a counterstain may be applied. Counterstaining is the practice of staining tissue components other than the tissue element of interest to provide greater visual contrast.

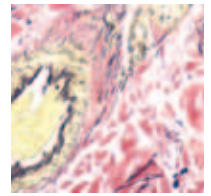
## Special Stains

The last step in all staining techniques is mounting or coverslipping the stained slide for microscopic evaluation. The method of choice depends on the staining technique.

For more information on the molecules and reactive mechanisms involved in specific special staining techniques, please refer to the appropriate Staining Methods chapter in this publication.

### References

1. Campbell NA. Biology. 3<sup>rd</sup> ed. Redwood City, CA: The Benjamin/Cummings Publishing Company, Inc.; 1993.
2. Carson FL. Histotechnology: A self-instructional text. 2<sup>nd</sup> ed. Chicago: ASCP Press; 1997.
3. Ebbing DD. General chemistry. 4<sup>th</sup> ed. Boston: Houghton Mifflin Company; 1993.
4. Perry JJ, Staley JT. Microbiology: dynamics and diversity. Fort Worth, TX: Saunder College Publishing; 1997.
5. Wolfe SL. Molecular and cellular biology. Belmont, CA: Wadsworth Publishing Company; 1993.



---

## Fixation and Tissue Processing

Jamie M. Holliday, HT (ASCP) and  
DakoCytomation Technical Support Group

### Fixation

An essential part of all histological and cytological techniques is to preserve cells and tissues as they naturally occur. To accomplish this, tissue blocks, sections or smears are usually immersed in a fixative fluid, although in the case of smears, merely drying the preparation acts as a form of preservation. The fixatives employed prevent autolysis by inactivating lysosomal enzymes and inhibiting the growth of bacteria and molds, which would give rise to putrefactive changes. Furthermore, fixatives stabilize the cells and tissues to protect them from the rigors of subsequent processing and staining techniques.

In performing their protective role, fixatives denature proteins by coagulation, by forming additive compounds or by a combination of coagulation and additive processes. The result is conformational changes in the structure of proteins and subsequent inactivation of enzymes. The newly formed complexes differ from the undenatured proteins in both chemical and antigenic profiles. The dilemma of fixation has always been that it is necessary to introduce some artifact in order to have a protective effect. By definition, fixatives alter the original chemical composition of the tissues involved.

In addition to altering the chemical nature of the cells and tissues to which they are applied, fixatives also cause physical changes to cellular and extracellular components. Viable cells are encased in an impermeable membrane. Fixation breaks down this barrier and allows relatively large molecules to penetrate and escape. Furthermore, the cytoplasm becomes permeable to macromolecules, forming a proteinaceous network sufficiently porous to allow further penetration of large molecules. It must be recognized, however, that different fixatives result in different degrees of porosity. Coagulant fixatives, such as B5 and formal sublimate, result in a larger pore size than do noncoagulant fixatives, like formalin.

Fixation is always a compromise, and the requirements of a fixative vary according to the different techniques employed in visualizing the structure of the cells or tissues. Thus, the techniques for cytology differ completely from those for histology or electron microscopy. In addition, the application of different staining methods necessitates other alterations in the fixation protocol, such as air-drying prior to Giemsa staining, and wet fixation for Papanicolaou's method.

### Paraffin-Embedded Sections

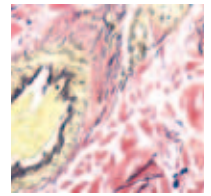
By far the largest proportion of samples used for histochemical staining is embedded in paraffin, and a number of fixatives have been formulated with this in mind. The most commonly used fixatives are discussed here. There are an abundance of specialty fixatives that will not be covered here but that may appear in literature references given in the bibliography.

Formalin containing 40% formaldehyde in water in addition to a neutral salt to maintain tonicity and often a buffering system to maintain pH is referred to neutral buffered formalin, or NBF. Large and small specimens are accommodated by this fixative because of its good penetration properties. NBF fixes not by coagulation, but by reacting primarily with basic amino acids to form cross-linking “methylene bridges.” This means that there is relatively low permeability to macromolecules and that the structures of intracytoplasmic proteins are not significantly altered. One common mistake using formalin fixatives is to underfix the tissue. Small (10×10×3 mm) tissue pieces fixed promptly in NBF for 6–24 hours will generally show good cytological preservation and nuclear detail. It is the great variation in time and fixation conditions that cause the majority of problems in histochemistry.

Because tissue fixation is critical in the events of histological staining, a technician must decide on the method of choice. Aspects to consider are temperature, size of the storage container, volume ratio, salt concentration, pH and incubation time. Formalin fixation is typically performed at room temperature. Using a low and wide specimen container to allow for adequate penetration and ease of retrieval by a technician is the best choice for adequate volume ratio. In addition, 1:20 volume ratio of fluid to tissue and 3–4 μm thickness is recommended for good penetration. To prevent swelling or shrinking of the cells, an isotonic solution is best. A pH of 7.2–7.4 is recommended to maintain ultrastructure and lessen cell distortion. When speaking of incubation, there are two aspects to consider: time elapsed since the sample was removed from the patient and time exposed to the fixative. The sooner the specimen is introduced to the fixative the better; the duration of exposure must be optimized for each fixative and specimen type.

Because each fixative preserves morphology differently, there are multiple options. For example, in structures like mucins, connective tissues, and urate crystals, the fixation technique is imperative to the morphology preservation. B5 fixative is used for its enhancing qualities of nuclear detail in mucin and bone marrow (hematopoietic) specimens. B5 works as a mordant using mercuric chloride as the active ingredient. Because of this process, mercury pigment can result if the tissue is not post-treated with iodine-sodium thiosulfate solution. The precipitate will appear as a fine, brown granular deposit on top of the tissue. Although the mechanism of Bouin's is unknown, the complementing effects of picric acid and acetic acid in the Bouin's solution also work well together to maintain morphology. Washing after the Bouin's step, like in the Masson's trichrome stain, is imperative to prevent continuing reaction of the picric acid, leading to loss of basophilia.<sup>1</sup> As with any rule, there is an exception. This is true in the case for urate crystal tissue processing. Urate crystals are represented as sodium urate in tissues and are soluble in water fixatives. Because of

## Fixation and Tissue Processing



this property, any specimen suspect for containing urates should be fixed in alcohols to prevent the leaching of urate crystals.

Following fixation, there are techniques available to the histotechnician to improve microtomy and staining quality. Each technique must be evaluated for each assay to preserve morphology and provide the best stain possible (Table 1).<sup>2</sup> The first method, going in chronological order of histology, is decalcification. This method is introduced to specimens that may be difficult to cut on a microtome because of calcium deposits. Decalcification can be achieved either by acids or by chelating agents. First, make sure the tissue has been adequately fixed and rinsed well to prevent any undesired reaction with the decalcifying agent. Strong acids can be used effectively if the end point is monitored accordingly. Nuclear detail is compromised if the acidic decalcifying agent is exposed too long to the specimen.<sup>3</sup> Because of the effects of acid on the pentose sugar of DNA, it is imperative to wash any excess acid from the tissue to prevent any further reaction. If nuclear detail is imperative to the staining, a chelating agent should be used. However, it is a much longer protocol than acid decalcification.

Table 1. Stain Optimization

Stain Technique	Thickness of Sections	Recommended Fixative	Fixatives to Avoid
AFB	3–4 µm FFPE smear	NBF 95%	
Bielschowsky	3–4 µm FFPE frozen	NBF	
Bodian	3–4 µm	NBF	
Congo Red	8–10 µm FFPE frozen	NBF	
PAS	3–4 µm FFPE frozen 10 µm	NBF	
Jones	2 µm FFPE	NBF	
GMS	3–4 µm FFPE smear	NBF 95%	
Urate Crystals	3–4 µm	alcohol	aqueous, NBF
Iron	3–4 µm smear	NBF air dry	
Reticulin	3–4 µm	NBF	
Snook's			
Gram	3–4 µm smear	NBF 95%	
Warthin-Starry	3–4 µm	NBF (critical)	
Helicobacter	3–4 µm	NBF	



## Special Stains

Table 1 (continued)

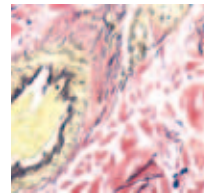
Stain Technique	Thickness of Sections	Recommended Fixative	Fixatives to Avoid
Masson's Trichrome	3–4 $\mu\text{m}$	NBF, Bouin's	
Colloidal Iron	3–4 $\mu\text{m}$	NBF	chromate
Copper	3–4 $\mu\text{m}$	NBF, B5 okay	Bouin's, decal
Rhodanine			
TRAP	smear	citrate/acetone	
Sudan Black	3–4 $\mu\text{m}$ frozen 10 $\mu\text{m}$	NBF	Bouin's
Leder	3–4 $\mu\text{m}$	NBF, B5	decal
Mast Cell	smear	CAF*	
TRAP	smear	citrate/acetone	
MPO +/- Fluoride	smear	alcoholic formalin	
Sudan Black	3–4 $\mu\text{m}$ frozen 10 $\mu\text{m}$	NBF	
Alcian Blue	3–4 $\mu\text{m}$	NBF	
Mucincarmine	3–4 $\mu\text{m}$	NBF	
Feulgen	3–4 $\mu\text{m}$	NBF	Bouin's
Gomori's Trichrome	3–4 $\mu\text{m}$	NBF	
Elastic Van Gieson	3–4 $\mu\text{m}$	NBF	
Oil Red O	3–4 $\mu\text{m}$	NBF	
Fontana Masson	3–4 $\mu\text{m}$	NBF	
Calcium	3–4 $\mu\text{m}$	NBF, alcohol	
Bile	3–4 $\mu\text{m}$	NBF	
PTAH	3–4 $\mu\text{m}$	B5	
Mallory's			
Luxol Fast Blue	3–4 $\mu\text{m}$	NBF	

\*CAF=citrate+acetone+formalin

### Frozen Sections

For histochemistry, cryostat sections give much faster results than paraffin sections. Additionally, fixative can be used with cryostat sections, allowing the histochemist to select a different and optimal fixative for each stain, all from the same sample. However, the morphological detail and resolution of the frozen sections are usually considerably inferior to tissue that has been embedded during specimen processing. Popular panels of frozen specimens performed in the histology lab are that of muscle and nerve biopsies.

Muscle and nerve biopsies are subdivided into paraffin, formalin-fixed preparation, snap-frozen section, electron microscopy section (EM) and, in some rare cases, biochemical



immunoblotting section. Because multiple techniques are required, multiple fixation processes are required as well. The routine H&E processing can be carried out by using formalin fixation techniques as previously mentioned. The specimen portion for frozen sectioning should be transported on top of wet ice and dampened saline gauze within 2 hours. Do not allow the tissue to freeze or soak up excess saline, as these will cause artifacts that can be seen microscopically and interfere with diagnostic interpretation. It has been suggested that talc powder can alleviate the moisture absorbance of the muscle tissue. This should be evaluated and quality tested before introducing it into a protocol. Upon receipt in the histology lab, orient in OCT (optimal cutting temperature) medium and flash freeze in liquid nitrogen/isopentane for optimal results. Orientation, size and expedient flash freezing are critical to a quality representation of the muscle cells. Similarly, for the EM portion, do not expose the tissue to any fixative. If transport time becomes excessive, fixation in 5% glutaraldehyde and 1% osmium tetroxide can be introduced. A detailed protocol should be advised by a specialist in electron microscopy. In some muscular degenerative disorders, biochemical techniques may be required. Flash freezing is typically performed in liquid nitrogen and in the absence of OCT embedding medium.

### Smears

Histotechnicians sometimes perform special stains on cytology smears, blood films and cytopreps from other ancillary departments within the laboratory. Increasingly, the commonly received cytoprep is that of the “thin prep.” These smears are wet-fixed immediately after preparation to preserve the fine structure of the chromatin and help in the evaluation of nuclear changes. The May-Grünwald Giemsa stain is routinely evaluated as a screening for atypical changes in the cervical lining. These smears are post-fixed routinely in 95% alcohol. In conjunction with tissue slides, a patient could have an air-dried counterpart sample to be evaluated. An example is bone marrow smears, usually received as an air-dried, fixed slide to be stained in parallel to the bone marrow core biopsy. A routine hemosiderin stain is still fairly common.

### Specimen Processing

Staining quality can be depreciated by inadequate fixation and similarly by poor tissue processing. A good technician must evaluate and determine the processing of choice for each assay, whether it is for special stains on paraffin, frozen or cell smear preparations. Paraffin processing, being the most common, has evolved and stabilized in the modern histology lab with the use of vacuum infiltration. It remains fundamentally important to remember the basics when processing and troubleshooting. The specimen processing methods presented in this chapter should be considered a brief introduction and may not include all the protocols adapted to the histology laboratory.

### Tissue Processing

In order to prepare a tissue for embedding, it must be infiltrated with paraffin. Because water and paraffin are not miscible in each other, tissues must be gradually dehydrated to achieve displacement of water with alcohol before the clearing agent is introduced. The size and penetrability of the tissue dictate how quickly this will occur. Heat is not recommended to accelerate the process, but automated vacuum processing may aid in efficiency of this step. Once successfully dehydrated, a clearing agent that is miscible with paraffin (i.e. xylene or substitute) is infiltrated through the tissue. Once again, an automated system may prove more efficient. Finally, the paraffin is introduced and completes the tissue for embedding. Keep in mind, individual laboratories must optimize to their specimen type. In general, needle biopsies and bloody specimens should be incubated conservatively, while fatty specimens can be processed longer.

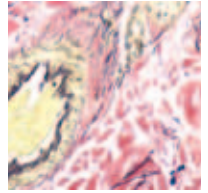
### Embedding and Microtomy

Once the tissue has been processed, it is ready to be orientated into a paraffin block and subsequently sectioned by microtomy. Orientation during embedding is crucial to get representation of proper morphology. Structures in skin, small GI (gastrointestinal), and vas deferens are examples in which orientation is especially critical. Good microtomy techniques will minimize artifacts that lead to difficult diagnostic interpretation of special stains. One of the most directly correlated factors is the thickness in which a specimen is cut. Routine H&E stained specimens are cut 3–4  $\mu\text{m}$ , but some morphology is best represented otherwise. For example, amyloid deposits are better represented at 10–12  $\mu\text{m}$ , whereas kidney biopsies should be cut at 2  $\mu\text{m}$  to represent glomeruli best. Techniques often used to aid in microtomy are water bath adhesive and positively charged slides. However, in silver impregnation stains, the silver ions are attracted to the coating and produce an overall background to the slide. To avoid this artifact, use clean slides without a coating.

After sectioning, the tissue slide is heated to dry the excess water and melt the wax surrounding the tissue section. Most special stain protocols allow for 68–72° C applied heat for approximately 15–20 minutes. However, some may limit the heat to below 60° C to preserve morphology. Refer to the recommendations on the specification sheet for each staining protocol. If not staining right away, paraffin dried slides may be stored at 2–8° C or room temperature, but it is best to cut specimens fresh for quality results.

### Technical Considerations

With any protocol, there are technical tips that can be considered. Make sure glass slides are clean and free from debris. Gentle washing and minimal thickness of cell layers will prevent the cells from detaching during staining protocols. Staining interpretation depends on adequate chemical spread and allocation. Make sure that there is enough sample to diagnose from and that the reagents have been applied evenly on the slides. If counterstaining is required, be sure to not over-incubate.



### References

1. Histological stains FAQ: decalcification. 1997; Available at: <http://www.vgernet.net/histology/decal.html>. Accessed Jan 6, 2004.
2. Sheenhan DC, Hrapchak BB. Theory and practice of histotechnology. 2<sup>nd</sup> ed. Ohio: Battelle Press; 1987.
3. Dapson RW. Speaker. Practical aspects of histology: solutions for today's problems, challenges for tomorrow. Battle Creed, MI: Anatech, LTD.

### Bibliography

1. Mendel S. Speaker. Fixation: first and foremost. New Orleans: American Society for Clinical Pathology; 2003.
2. Atwood K, Farmilo AJ, Stead RH, Boenisch T. Fixation & tissue processing. From: Handbook for immunochemical staining methods. 3rd ed. Carpinteria, CA: DakoCytomation; 2003. p. 18–22, 44–6.
3. Leong A. Fixation and fixatives. 2000. Available at: <http://home.primus.com.au/royellis/fix.htm>. Accessed January 6, 2004.
4. Internal quality control testing: principles & definitions. NCCLS document C24-A; vol 11, number 6.
5. Stead RH, et al. Can J Med Technol 1985; 47: 162–70, 178.
6. Baker JR. Principles of biological microtechnique. London: Methuen; 1970.
7. Lillie RD. Histopathologic technique and practical histochemistry. 3rd ed. New York: McGraw Hill; 1965.
8. Henry JB. Clinical diagnosis & management by laboratory methods. 18th ed. Philadelphia: W.B. Saunders; 1991. p. 621–622.

## Staining Methods: Nucleus and Cytoplasm

Rick Couture, BS, HTL (ASCP), Laurie J. Hafer, PhD

### The Cell

Cells are the fundamental building blocks of the human body. All primitive cells begin with similar morphology; however, as each cell develops, it becomes a specialized unit, by a process known as cell differentiation. During cellular differentiation, each cell undergoes chemical and morphological changes. The morphology of each differentiated cell varies with its function.

Most cells are composed of two basic components, the nucleus and the cytoplasm (See Chapter 2, Figure 1: The Cell). The only cells that do not contain a nucleus are mature red blood cells and platelets. The nucleus is usually found near the center of the cell and can be round, elongated or lobed. The main components of a nucleus are a nuclear membrane, chromatin, and a nucleolus. The nuclear membrane surrounds the nucleus. Chromatin is the genetic material contained within the nucleus, which consists of deoxyribonucleic acid (DNA) and proteins. The nucleolus is composed mostly of proteins, but produces the majority of ribonucleic acid (RNA), which is used to manufacture proteins. Most cells have only one nucleolus; however, the nucleus of cells that are extremely active may contain more than one nucleolus. The nucleus is considered the brain of the cell, where genetic information is stored and cell division begins, by a process known as mitosis.

The second basic component of the cell is the cytoplasm. The cell membrane is the outermost layer of the cell. The cytoplasm is what lies between the cell membrane and the nuclear membrane. The cytoplasm contains a matrix, known as the cytoskeleton, which maintains the shape of the cell and also holds embedded structures in place. These embedded structures are classified into two groups, organelles and inclusions. Organelles are the cellular machinery that participate in cellular metabolism. The main organelles are the Golgi apparatus, endoplasmic reticulum and mitochondria. Inclusions are the cellular products or metabolites of the organelles, such as pigments, lipids, proteins or carbohydrates.

### Hematoxylin and Eosin

#### Clinical Applications

The most commonly used histological stain is Hematoxylin and Eosin (H&E) (Figure 1). It is a relatively simplistic staining technique that takes advantage of the acidic and basic properties of the cell's cytoplasm and nucleus to stain a wide variety of tissues and tissue structures. In anatomic pathology and histology laboratories, the H&E stain is routinely performed on all specimens and is the core stain for all microscopic diagnoses. All requests for special staining techniques arise from the microscopic evaluation of the

## Staining Methods: Nucleus and Cytoplasm

---



H&E. The anatomic pathologist uses the H&E to diagnose disease, identify cancer, confirm a metabolic disorder or identify tissue type.

With H&E, hematoxylin stains the nuclei blue, and eosin stains the cytoplasm pink. Variations in the numerous H&E staining techniques introduce variations in the colors or shades of blue and pink obtained with hematoxylin and eosin. Intranuclear detail or distinct staining showing the interior of the nucleus is an important part of a good H&E stain.

### Chemistry

Hematoxylin is extracted from the *Hematoxylin campechianum* tree. At this point, it should be noted that hematoxylin is not the actual product that is used as a stain. Hematein, the oxidation product of hematoxylin, is what is used as the natural dye. Despite the errant nomenclature, the term hematoxylin will be used throughout this chapter because of its familiarity to the histotechnology community. Exposure of hematoxylin to light and air creates the conditions necessary for natural oxidation or ripening, resulting in the end product, hematein. The natural process is very slow; therefore, chemical oxidation methods have been used to accelerate the process. Two commonly used oxidizing agents are sodium iodate and mercuric chloride. Examples of naturally oxidized hematoxylin are Ehrlich's and Delafield's hematoxylin; chemically oxidized hematoxylin are Mayer's and Harris' hematoxylin. Overall, naturally oxidized hematoxylin have a longer shelf life than chemically oxidized hematoxylin.

Hematein dye alone has poor affinity for tissue; therefore, a mordant must be added. The dye-mordant combination, or "lake," is typically formed when hematein is combined with a metal salt. A common mordant teamed with hematein is the metal salt, aluminum potassium sulfate. Other mordants are salts of iron, tungsten, molybdenum and lead. When the hematein and mordant are combined, the hematoxylin lake can then strongly bind to tissue elements, such as nuclear chromatin. The process by which the affinity of the hematoxylin lake is altered such that it can bind to nuclear chromatin is not yet fully understood. Hematoxylin solutions are classified based on the mordant. For example, if iron salt is the mordant, then the hematoxylin lake is classified as an iron hematoxylin (Table 1).

## Special Stains

Table 1. Common Hematoxylin

Mordant	Oxidant	Stain	Applications
Aluminum	Natural	Ehrlich	Nuclear stain with eosin; some mucins
Aluminum	Natural	Delafield	Nuclear stain with eosin
Aluminum	Sodium iodate	Mayer	Nuclear stain with eosin; counterstain
Aluminum	Mercuric oxide	Harris	Nuclear stain with eosin
Aluminum	Iodine	Cole	Nuclear stain with eosin
Aluminum	Potassium iodide	Carazzi	Nuclear stain with eosin; counterstain (frozen sections)
Aluminum	Sodium iodate	Gill	Nuclear stain with eosin
Iron	Natural	Weigert	Nucleus, with acid dyes
Iron	Natural	Heidenhain	Intranuclear detail, muscle striations
Iron	Natural	Verhoeff	Elastic fibers
Iron	Natural	Loyez	Myelin
Tungsten	Natural or potassium permanganate	Mallory PTAH	Fibrin, muscle striations, glial fibers
Molybdenum	Hydrogen peroxide	Thomas	Collagen, endocrine cell granules
Lead	None	Solcia	Endocrine cell granules
None	None	Mallory	Iron, copper, lead

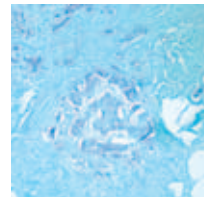
Source: Bancroft et al.

Because the aluminum hematoxylin produce good nuclear staining these hematoxylin are routinely used for H&E stains. A significant drawback to using aluminum hematoxylin is that these dyes are removed from the tissue when any step following their application involves an acidic solution. Iron hematoxylin is often employed as the nuclear stain when the special staining technique requires acidic solution to be applied subsequent to the hematoxylin step. A few special staining techniques that utilize iron hematoxylin for this reason are elastic stains, Masson's trichrome, Gomori's trichrome and mucicarmine.

The counterpart to hematoxylin in the H&E stain is eosin. There are several types of eosin, but eosin Y is the most widely used for this stain. The complementary pairing of eosin and hematoxylin produces a stain that most clearly demonstrates tissue structure and cellular architecture. Eosin stains both cytoplasm and connective tissue fibers differentially. This means that with a single application of the dye, varying shades of pink will demonstrate several types of cells and connective tissue fibers. For example, the cytoplasm of epithelial cells, red blood cells, collagen and the cytoplasm of muscle cells will stain different shades of pink, within the same tissue section. Phloxine is often added to the eosin preparation to increase the number of pink shades seen. As with any special staining technique, the staining intensity and degree of differentiation is ultimately the preference of the anatomic pathologist reading the slide.



## Staining Methods: Nucleus and Cytoplasm



The H&E stain can be performed either as a progressive or regressive stain. In the progressive method, tissue is stained with hematoxylin for a specified period of time, such that the nuclei are appropriately stained. At this point in the staining process, the background will be virtually unstained. Following the hematoxylin step, the slide can be rinsed in tap water or a basic solution, also known as bluing reagent, to increase the intensity of the blue nuclear staining. Eosin is then applied to selectively stain the cytoplasm and connective tissue. Conversely, the regressive method overstains the tissue section with hematoxylin, leaving blue coloring on all tissue components. The next step is to remove the excess blue coloring by differentiating the tissue section in an acid alcohol solution. The tissue section is then placed in bluing reagent to intensify the blue nuclear staining. The final step is counterstaining the tissue section with eosin.

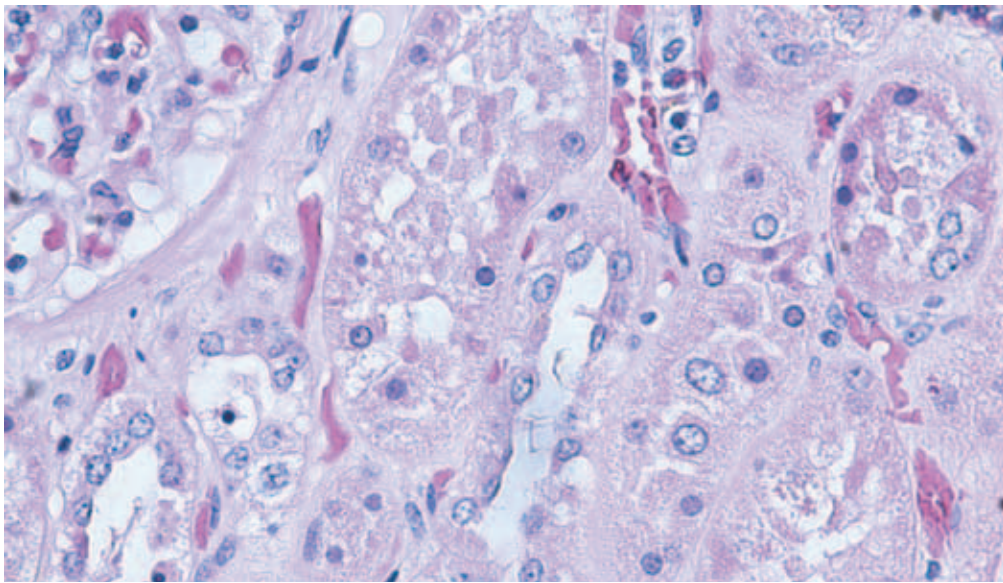


Figure 1. The H&E stain is the most widely used histological stain. In this kidney specimen, nuclei appear blue, and the cytoplasm is pink. (DakoCytomation Artisan)

### Results

Feature	Visualization
Nuclei	Blue
Cytoplasm	Pink
Red blood cells, eosinophilic granules, other tissue elements	Varying shades of pink

### Technical Considerations

Table 2 offers a guideline for staining with aluminum hematoxylin. Several factors can affect these times.

- Age of the hematoxylin
- Intensity of the stain or number of times the hematoxylin has been reused
- Progressive or regressive staining technique
- Tissue fixation or pretreatment



## Special Stains

Table 2. Staining with Aluminum Hematoxylin

Stain	Time
Cole's	20–45 minutes
Delafield's	15–20 minutes
Ehrlich's (progressive)	20–45 minutes
Mayer's (progressive)	10–20 minutes
Mayer's (regressive)	5–10 minutes
Harris' (progressive for cytology)	4–30 seconds
Harris' (regressive)	5–15 minutes
Carazzi's (progressive)	1–2 minutes
Carazzi's (regressive)	45 seconds
Gill's (regressive)	5–15 minutes

Source: Bancroft et al.


Although personal preference plays a significant role in the visual interpretation of what constitutes a good H&E, some guidelines for an optimally stained slide should not be overlooked. Assuming that all controllable factors (i.e. fixation, processing, embedding) have been optimally performed, each H&E slide should demonstrate the following characteristics.

- Nuclear chromatin should be blue and very distinct; the shade of blue may vary from blue to black.
- The nucleolus in most cells should exhibit a reddish or reddish-purple color.
- Cytoplasm should demonstrate a pink color; the shade of pink may vary from pink to orange.
- Eosinophilic granules should be well defined and appear orange-red.

If optimal staining is not achieved, the following troubleshooting tips may provide helpful insight into the potential cause (Table 3).

Table 3. Troubleshooting an H&E Stain

Appearance	Possible Cause
Nuclear chromatin is not stained	Hematoxylin solution may be too old; Tap water used for bluing and washing slides could contain too much chlorine.
Nuclear chromatin stains red to purple in color	Bluing is performed in water that is too acidic; Bluing time is insufficient; Bluing solution may be too old.
Nuclear chromatin is gray in color	Hematoxylin solution has been over-oxidized.
Nuclear chromatin is brown in color	Hematoxylin has been severely over-oxidized, which may be a result of the preparation or long-term exposure to air or sunlight.
Red tissue section, including nuclei	The slide has been over-differentiated in acid alcohol or overstained in eosin; Hematoxylin may be too old; Eosin differentiation is incomplete.



### Nucleic Acids

#### Clinical Applications

There are two types of nucleic acids, deoxyribonucleic acid (DNA) and ribonucleic acid (RNA). DNA and RNA differ only in the chemical structure of a sugar group. DNA has a 5-carbon sugar called deoxyribose, and RNA contains a 5-carbon sugar called ribose. The difference in these sugars is a single hydroxyl group ( $\text{OH}^-$ ), and it is this difference that allows for selective demonstration of DNA and RNA by special staining techniques. The two most common special staining techniques utilized for visualizing nucleic acids are the Feulgen and methyl green-pyronin Y stains.

#### Feulgen Stain

The Feulgen stain (Figure 2), first described in 1924, takes advantage of the ability of hydrochloric acid to hydrolyze or chemically alter the deoxyribose sugar of DNA into an aldehyde. Hydrolysis is the process by which a chemical compound decomposes by reacting with the elements of water. The resulting aldehyde reacts with Schiff's reagent, which specifically binds to aldehydes. This combination of acid hydrolysis and aldehyde staining is what constitutes the Feulgen reaction. A light green counterstain is often applied to the tissue section to achieve a better contrast. The ribose sugar of RNA is unaffected by this acid hydrolysis and, therefore, will not stain.

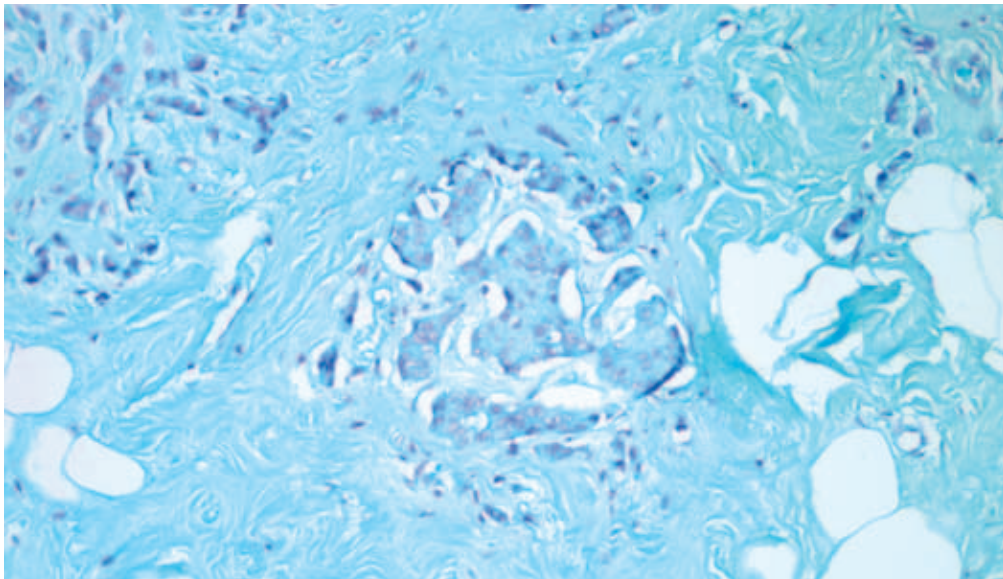


Figure 2. This Feulgen stain demonstrates DNA (magenta) in aneuploid breast carcinoma tissue. (DakoCytomation Artisan)

### Results

Feature	Visualization
DNA	Magenta
Background	Light green

### Technical Considerations

In the Feulgen stain, hydrolysis is the most critical step. As the hydrolysis time is increased, an increasingly stronger reaction can be achieved until an optimal state is reached. Continued hydrolysis past this optimal state causes the reaction to become weaker and ultimately fail. Table 4 offers a guideline for hydrolysis based on the tissue fixative used.

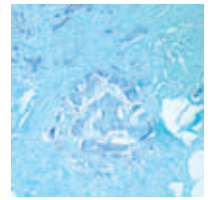
Table 4. Suggested Hydrolysis Times Based on Fixation

Fixative	Time (min.)
Bouin's	Unsuitable
Carnoy's	8
Flemming's	16
Formaldehyde vapor	30–60
Formalin	8
Formal-sublimate	8
Helly's	8
Newcomer's	20
Regaud's	14
Regaud's-sublimate	8
Susa's	18
Zenker's	5
Zenker's-formol	5

Source: Bancroft et al.

### Methyl Green-Pyronin Y Stain

The methyl green-pyronin Y stain is used to demonstrate RNA. This special staining technique was first published in 1899 but has undergone several modifications since that time. Tissue sections are incubated in a solution of purified methyl green and pyronin Y. Methyl green preferentially binds to DNA and pyronin Y to RNA. The reason that two basic dyes bind preferentially is suggested to be related to the different degrees of polymerization observed in DNA and RNA. DNA, which is more highly polymerized, is bound only by methyl green; whereas RNA, which is less polymerized than DNA, is bound only by pyronin Y. Depolymerization studies support this hypothesis.



### Results

Feature	Visualization
RNA	Red
DNA	Green or blue-green
Background	Pale pink to colorless
Mucins, epithelium, cartilage	Pink to red

### Technical Considerations

There are several key components to this special staining technique: fixation, solution preparation and dehydration. Typically, Carnoy's fixative yields the best results, though protocols have been modified to allow formalin fixed tissues to be stained. The pH of the dye solution, purity of the methyl green and concentration of the two dyes are all critical parts of this stain. The pH and dye concentrations can be altered to optimize this stain for different tissue types. After staining, it is imperative that the stained slides are not exposed to water. The slides should be dehydrated in acetone or tertiary butanol and mounted in a synthetic resin.

## Polychromatic Stains

### Clinical Application

The polychromatic Giemsa stains for hematopoietic tissues are another group of nuclear and cytoplasmic special staining techniques. These stains are used to identify the different cell lineages found in hematopoietic tissues, such as spleen, bone marrow and blood. Hematopoietic tissues are where red blood cells and white blood cells are formed. These blood cells begin as primitive cells and progress through many stages of development to ultimately become mature red and white blood cells. Some examples of mature white blood cells are neutrophils, eosinophils, basophils and lymphocytes. Anatomic pathologists use these polychromatic stains to aid in diagnosing tumors and blood disorders, such as leukemia and lymphoma.

### Chemistry

Romanowsky-Giemsa stains are the traditional name for the solutions used in these stains. The staining properties of the solutions were first described in 1891 by hematologists, Romanowsky and Giemsa. The most commonly used Romanowsky-Giemsa stains are the Wright's and Leishman's Giemsa stains and the modified Wolbach's and May-Grünwald Giemsa stains. The Wright's and Leishman's Giemsa stains are mainly used for bone marrows and blood, whereas the modified Wolbach's and May-Grünwald Giemsa stains are typically used for tissue sections, such as spleen. The basic principle underlying all Giemsa stains is that a basophilic or basic dye, methylene blue, is combined with eosinophilic or acidic dyes – eosin, azure A and azure B – to create “neutral dyes” that demonstrate a wide variety of colors when used to stain hematopoietic cell nuclei and platelets. The

## Special Stains

creation of the “neutral dyes” is the reason these stains are called polychromatic stains, or stains of many colors (Figure 3). A key step in these special staining techniques is to differentiate the stain using a weak acid solution. This differentiation enhances the colors that each cell type stains, allowing the anatomic pathologist to identify the different cell types and stages of cellular development. With Giemsa stains in particular, it is the cellular morphology and nuclear and cytoplasmic detail of the cells that are critical for correct identification of cell types, so that an accurate diagnosis can be made.

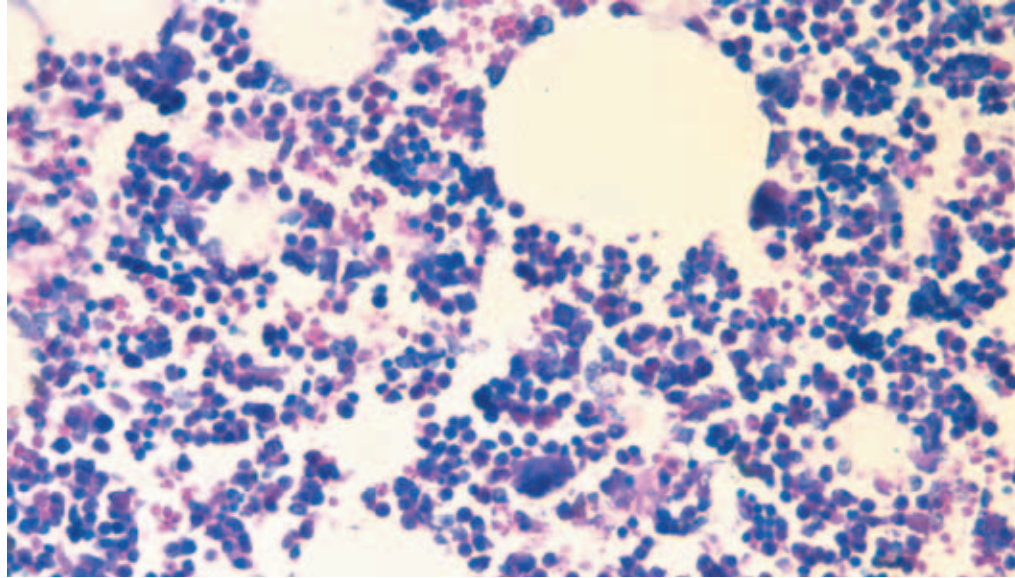


Figure 3. Giemsa stains, shown here on bone marrow, are used to identify the various cell lineages present in hematopoietic tissues. (Dako Autostainer)

### Results

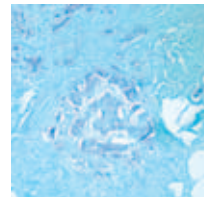
Feature	Visualization
Basophils	Dark blue to violet/purple
Eosinophils	Pink
Leukocytes	Purple
Neutrophils	Purple
Platelets	Blue to purple
Red blood cells	Pink to red
Cartilage	Purple
Nucleus	Blue

### Technical Considerations

Due to the various hematopoietic tissues that can be stained with Giemsa stains, the pH of the solutions and buffers can be critical for a successful stain. Different fixation methods may also create the need to alter the pH of solutions and buffers to achieve the appropriate staining patterns. The Giemsa working solution does not tend to be stable,

## Staining Methods: Nucleus and Cytoplasm

---



so it should be made fresh each time the stain is performed. Adjusting the time in the weak acid differentiating step may also aid in balancing the colors.

### References and Suggested Reading

1. Junquera LC, Carneiro J. Basic histology. 3rd ed. Los Altos, CA: Lange Medical Publications; 1980
2. Lee GL. Histopathologic methods and color atlas of special stains and tissue artifacts. Gaithersburg, MD: American Histolabs Inc., Publications Division; 1992.
3. Bancroft JD, Stevens A, editors. Theory and practice of histological techniques. 4th ed. New York: Churchill Livingstone; 1996.
4. Sheehan DC, Hrapchak BB. Theory and practice of histotechnology. 2<sup>nd</sup> ed. St. Louis, MO: The C.V. Mosby Company; 1980.
5. Carson FL. Histotechnology: a self-instructional text. 2<sup>nd</sup> ed. Chicago: American Society of Clinical Pathologists Press; 1996.

## Staining Methods: Connective Tissue, Muscle Fibers and Lipids

Mary Cheles, MPH, HTL, DLM (ASCP)

### Connective Tissue

Connective tissue is the most abundant tissue and is located throughout the body. It provides a protective and supportive framework for organs and other body structures. Connective tissue is composed of some cells and a proportionally greater content of extracellular material (matrix). Cells commonly found in connective tissue are fibroblasts, mast cells, macrophages and adipose cells. They vary depending on the type of connective tissue in which they are located. Blood leukocytes and plasma cells are also seen, as most connective tissue is well vascularized. Connective tissue cells are often not in contact with one another but widely dispersed within the matrix. Connective tissue cells function in a variety of ways that include combating and ingesting foreign proteins and secreting various components that contribute to the matrix.

In addition to cells, the matrix consists of various fibers and an amorphous ground substance that occupies the space between the fibers and the cells. The amorphous ground substance in connective tissue is nonliving and consists of carbohydrate and protein-derived material that may be fluid, semi-fluid, gel-like or fibrous in consistency.

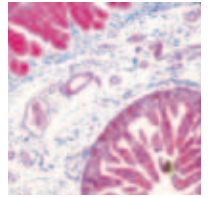
The three types of fibers present in connective tissue matrix are reticular, collagenous and elastic fibers.

- Reticular fibers are composed of the protein collagen and are coated with glycoprotein. They form a delicate framework for many soft organs and a network around nerve fibers, fat cells, lymph nodes and smooth and skeletal muscle fibers.
- Collagenous fibers are composed of the protein collagen and provide the greatest strength of the three fiber types. Collagenous fibers are found in ligaments, tendons, cartilage and bone.
- Elastic fibers are composed of the protein elastin and offer the greatest flexibility among the fiber types. Elastic fibers allow tissue to stretch and are located in the skin and walls of blood vessels.

Connective tissue types vary, with each type characterized by the pattern and proportion of cells and the composition of the matrix. Adult connective tissue is subdivided into four categories.

- Connective tissue proper: Loose (areolar), dense, reticular, elastic and adipose
- Cartilage: Fibrocartilage, elastic and hyaline cartilage
- Osseous tissue: Cancellous (spongy) and cortical (dense)
- Vascular tissue: Blood and blood-forming





This chapter will focus on staining methods demonstrating cells and fibers in the subgroup of connective tissue proper.

### Reticular Fibers

#### Clinical Applications

Reticular fibers perform a support function in the body and are common in the liver, kidney and spleen. A cirrhotic liver shows disturbed patterns of reticular fibers, explaining the routine use of reticular stains in liver biopsy specimens. Reticular fibers also display characteristic patterns in tumors, thereby aiding in the differential diagnosis of certain tumor types.

#### Chemistry

Reticular fibers are commonly demonstrated by the use of stains involving silver solutions (Figure 1). These stains rely on the impregnation of silver ions to the fibers and subsequent reduction of those silver ions to their visible metallic form. Reticular fibers are agyrophilic in that they possess the ability to adsorb silver from solution but are unable to reduce it to visible metallic form without the use of a reducing solution to drive the reaction. Currently, there are many modifications of silver stains utilized to demonstrate reticular fibers (Gomori, Snook, Gordon & Sweets, etc). However, most rely on the same chemical principles for success. Demonstration of reticular fibers generally employs an ammoniacal silver solution as a source of silver ions.

An ammoniacal silver solution consists of a strong base (ammonium hydroxide) added to an aqueous silver nitrate solution to form a silver diamine complex. This method commonly calls for oxidation and sensitization of tissue prior to application of this complex. Oxidation (potassium permanganate/periodic acid) enhances subsequent staining, while the sensitizing agent (uranyl nitrate/dilute silver nitrate) initially binds to the tissue component of interest. Silver ions provided by the ammoniacal silver solution impregnate the fibers and replace the sensitizer in the metal-organic compound. Subsequently, by the action of a reducing agent (formalin), the silver diamine complex is reduced to visible metallic form. Metallic silver is converted by use of a toning reagent (gold chloride) to metallic gold, which is more stable and offers better contrast and clarity. Unreduced silver and excess gold chloride are removed (sodium thiosulfate), and the tissue section is then counterstained, if desired. Nuclear fast red or light green counterstains are commonly used. A section of normal liver or tonsil tissue may be used for quality control.



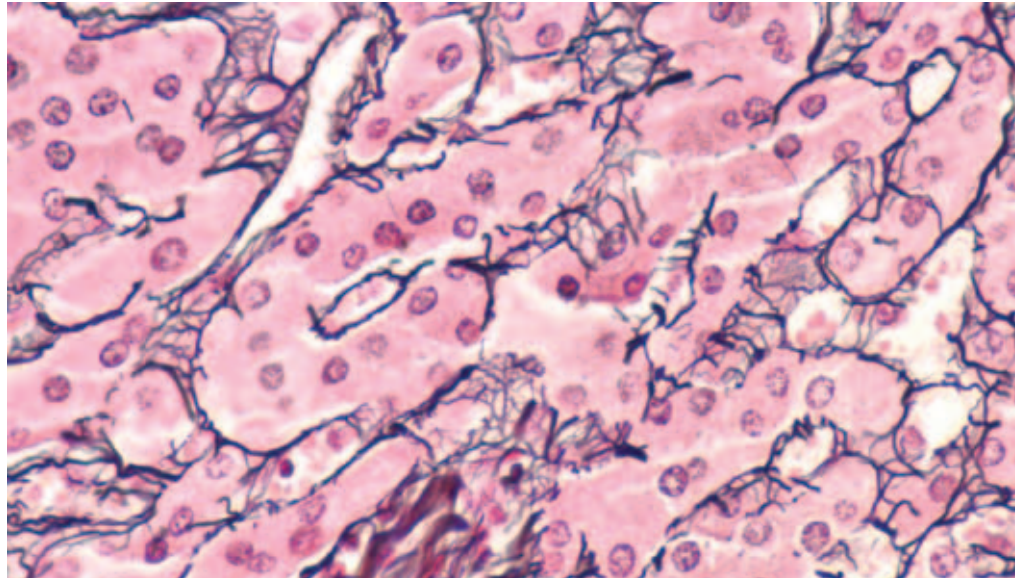


Figure 1. The reticulin nuclear fast red stain is used for visualization of reticulin fibers in tissue section. The reticulin fibers in this liver section are stained black with an ammoniacal silver nitrate solution. All background tissue elements are stained pink to red with nuclear fast red. (DakoCytomation Artisan)

### Results

Feature	Visualization
Reticular fibers	Black, fine linear pattern
Nuclei	Taupe/color of counterstain selected
Other tissue elements	Taupe/color of counterstain selected

### Technical Considerations

- Non-selective silver precipitation on tissue sections may be caused by use of improperly cleaned glassware.
- Silver solution should be made fresh with high quality water.
- Excess ammonium hydroxide added to ammoniacal silver solution impairs impregnation of reticular fibers and results in weak staining.
- Alkalinity of silver solution may contribute to loss of tissue section from slide. The use of charged or adhesive-coated slides is recommended.

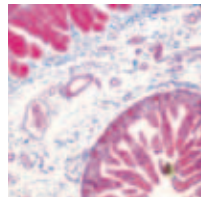
### Basement Membranes

#### Clinical Application

The basement membrane is a modified connective tissue that provides support to epithelial cells, muscle fibers and peripheral nerves. It also functions to permit diffusion of nutrients and wastes between cells and capillaries in underlying connective tissue.

## Staining Methods: Connective Tissue, Muscle Fibers and Lipids

---



The Jones methenamine silver stain is excellent for the demonstration of glomerular and tubular basement membranes of kidney biopsies. It is routinely used as a component of kidney biopsy panels to demonstrate evidence of renal disease.

### Chemistry

Basement membranes are commonly demonstrated with a silver stain employing a methenamine silver solution (Figure 2). Methenamine silver methods rely on the oxidation of carbohydrates within the tissue to form aldehyde groups. These groups will directly act to reduce silver ions from the methenamine silver solution to metallic silver. The ability to bind silver ions from solution and independently reduce silver to a visible metallic form is referred to as argentaffin. The use of sensitizing and reducing solutions are not necessary with this method.

Oxidation by periodic acid or chromic acid enhances subsequent staining. A working methenamine-silver nitrate solution provides silver ions for impregnation. Gold chloride tones tissue sections and converts metallic silver to metallic gold. Unreduced silver and excess gold chloride are removed by sodium thiosulfate. The tissue section is then counterstained, if desired. Light green is commonly used. Normal kidney tissue may be used for quality control.

Basement membranes may also be demonstrated using the Periodic Acid-Schiff (PAS) technique. Please see the Carbohydrates & Amyloid chapter for more information.

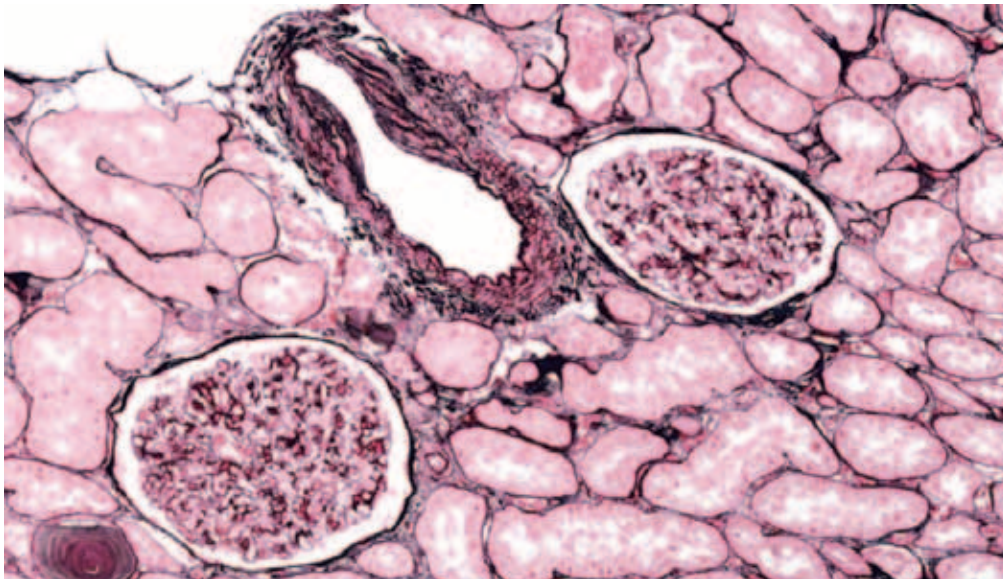


Figure 2. The Jones basement membrane stain is used for visualization of basement membranes, specifically glomerular and tubular basement membranes in renal tissue. (DakoCytomation Artisan)

### Results

Feature	Visualization
Basement membrane	Black
Nuclei	Taupe/light green
Other tissue components	Taupe/light green

### Technical Considerations

- Glassware should be acid-cleaned and rinsed in distilled water prior to use.
- Incomplete impregnation will result in weak, interrupted staining patterns of the glomerular basement membrane. Incubation time may need adjustment.
- Counterstaining should be delicate to avoid obscuring positive reaction.

### Elastic Fibers

#### Clinical Application

Elastic fiber demonstration is useful to identify atrophy caused by arteriosclerotic changes, evidence of other vascular diseases, and vessel invasion by tumors.

#### Chemistry

The Verhoeff-Van Gieson (VVG) stain, commonly used to demonstrate elastic fibers (Figure 3), is an example of a regressive staining method. The tissue section is initially overstained with a solution of hematoxylin-ferric chloride-iodine and then differentiated for optimal demonstration of elastic fibers. Ferric chloride and iodine act as a mordant to link hematoxylin dye molecules to tissue components. They then act as oxidizers to convert hematoxylin to hematein. A dilute solution of ferric chloride is then used to break the tissue-mordant-dye complex, thereby differentiating structures within the tissue. As elastic fibers have a strong affinity for the iron-hematoxylin complex, they will retain dye molecules, while other structures dissociate dye molecules. The result is a positive stain reaction. Distilled water washes followed by sodium thiosulfate remove excess iodine and ferric chloride from tissue sections. Van Gieson solution acts as a counterstain. Common quality control tissues include lung parenchyma, artery and skin.

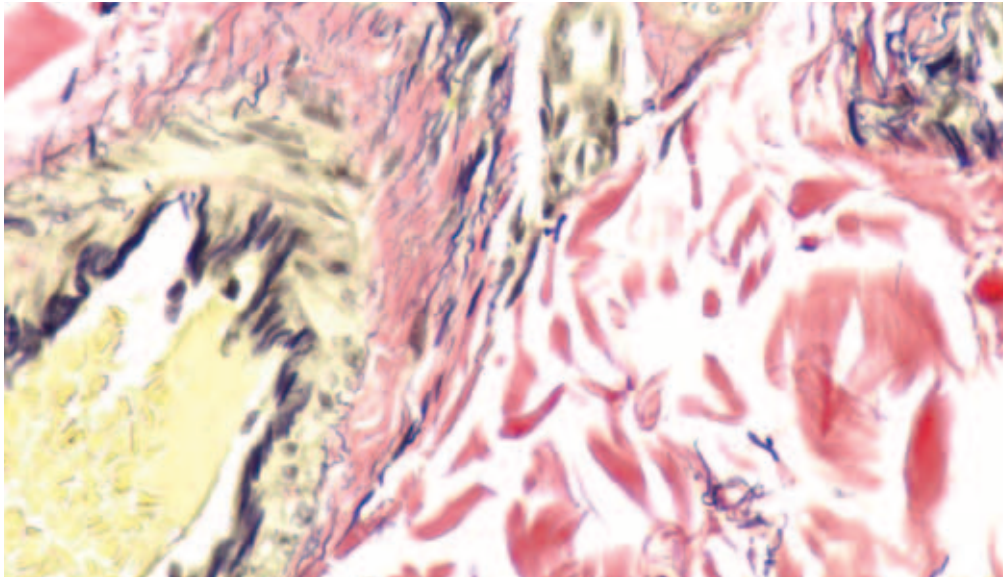
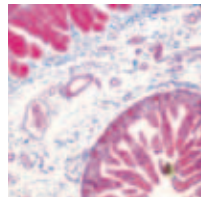


Figure 3. This Verhoeff-Van Gieson stain is used to visualize elastic fibers in skin tissue. (DakoCytomation Artisan)

### Results

Feature	Visualization
Elastic Fibers	Blue-black to black
Nuclei	Blue to black
Collagen	Red
Other Tissue Elements	Yellow

### Technical Considerations

- Verhoeff solution should be made fresh for each use.
- The differentiation step is critical to optimal results, as over-differentiation results in loss of finer fibers.
- Prolonged staining in van Gieson counterstain will continue to differentiate section due to its picric acid component.

### Mast Cells

#### Clinical Application

Mast cells are identified in varied inflammatory conditions, particularly in skin. A toluidine blue stain is commonly used (Figure 4).



### Chemistry

Mast cells contain granules of histamine and heparin and are metachromatic. Reaction of these granules with toluidine blue causes them to stain a different color than that of the dye solution. Skin is a good quality control tissue.

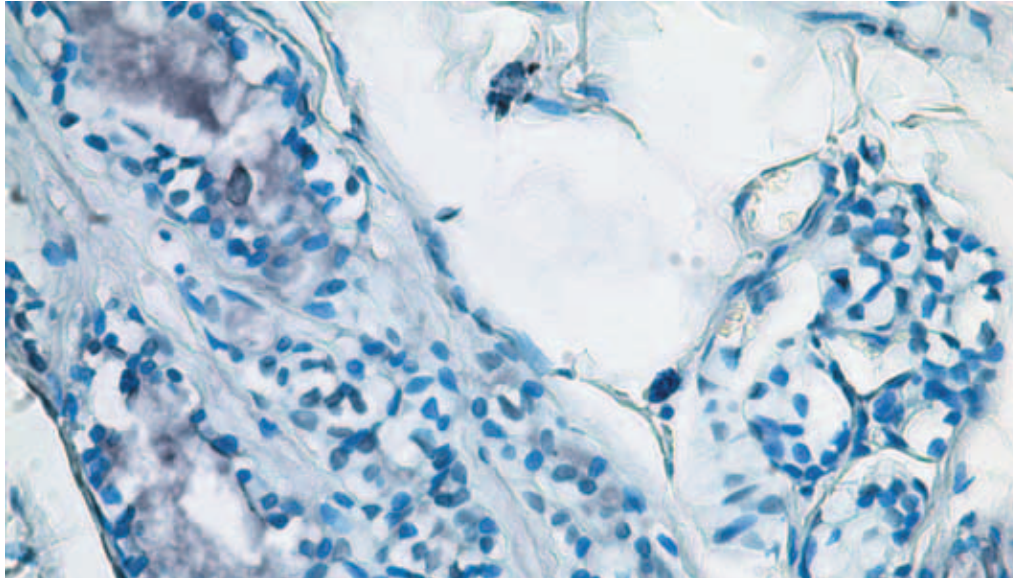


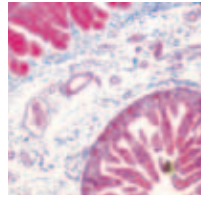
Figure 4. Toluidine blue demonstrates mast cells in this breast specimen.

### Results

Features	Visualization
Mast cells	Deep violet
Background	Blue

### Technical Considerations

- Prompt fixation of tissue is recommended as delays may cause granules to deteriorate.



### Muscle

Muscle cells are characterized by the ability to contract, providing the movement necessary for locomotion of an organism and movement of materials within an organism. Three types of muscle tissue are identified based on their arrangement of actin and myosin fibers.

- Skeletal muscle cells are multinucleate and contain bands referred to as striations. These cells are typically arranged in bundles attached to skeletal elements. They are controlled by motor neurons and are responsible for locomotion.
- Cardiac muscle cells display centrally located nuclei within the interconnecting fibers (intercalated discs). Cardiac muscle is found only in heart tissue, which provides constant rhythmic contraction without the need for outside stimulation.
- Smooth muscle cells are spindle-shaped with a central nucleus. Smooth muscle is located in the skin and many internal organs, including the digestive and reproductive systems. They are responsible for involuntary motions such as peristalsis.

### Trichrome Stains

#### Clinical Application

Trichrome stains are used to distinguish collagen from muscle and aid in the diagnosis of fibrotic changes, neuromuscular diseases and tumors of muscle origin.

#### Masson's Trichrome

#### Chemistry

With the Masson's trichrome stain (Figure 5), Bouin's solution is used initially as a mordant to link the dye molecules to the tissue components of interest. Nuclei are stained with Weigert's hematoxylin, an iron hematoxylin, which is resistant to decolorization by subsequent acidic staining solutions. Application of Biebrich-scarlet-acid-fuchsin stains all acidophilic tissue elements such as cytoplasm, muscle and collagen. Subsequent treatment by phosphomolybdic/phosphotungstic acid serves as a decolorizer causing the Biebrich-scarlet-acid-fuchsin to diffuse out of the collagen fibers while leaving the muscle cells red. Subsequent application of aniline blue will stain the collagen after which, 1% acetic acid is employed to properly differentiate the tissue section. Most tissue will contain an internal quality control, but appendix, fallopian tube, uterus or small intestine may be used.

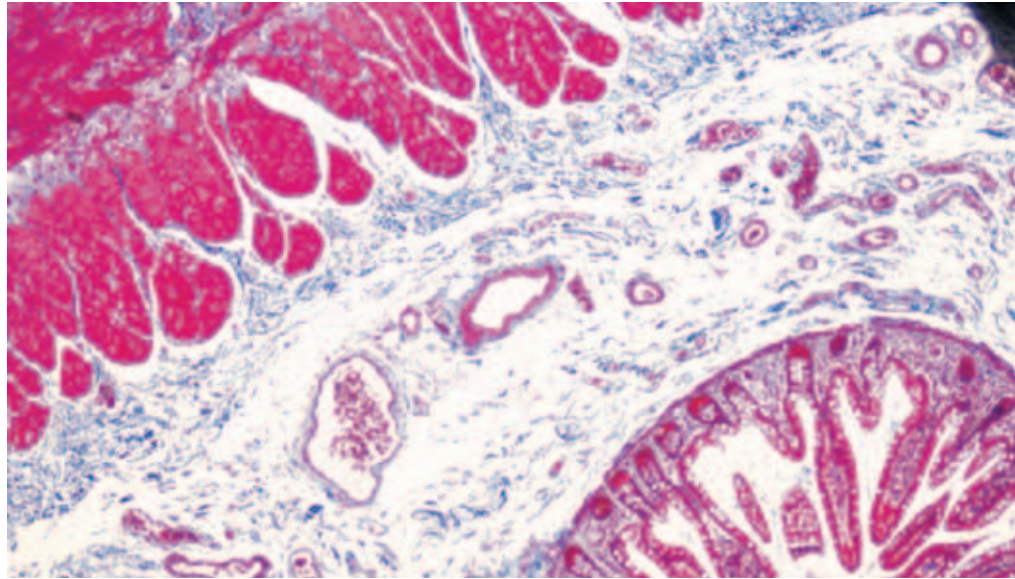


Figure 5. Masson's trichrome stain is used to distinguish collagen from muscle in tissue specimens. (DakoCytomation Artisan)

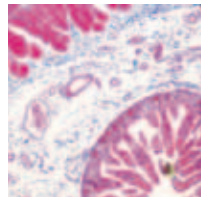
### Results

Feature	Visualization
Muscle, cytoplasm, erythrocytes	Red
Nuclei	Black
Collagen, mucus	Blue

### Technical Considerations

- Viable Bouin's solution used at the correct temperature will ensure optimal staining.
- Proper differentiation by phosphomolybdic/phosphotungstic acid yields proper intensity of red-staining entities.
- Decreased red staining of muscle may indicate that Biebrich-scarlet-acid-fuchsin solution has aged.
- Intensity of blue-staining entities is modified by increasing/decreasing incubation time of aniline blue.
- Faded blue staining of connective tissue may indicate overdifferentiation of section by 1% glacial acetic acid.





### Gomori's One-Step Trichrome Stains (Green or Blue)

#### Chemistry

One-step trichrome stains (Figure 6) combine a plasma stain (chromotrope 2R) and a connective tissue stain (fast green/light green or aniline blue) in a solution containing phosphotungstic acid and glacial acetic acid. Bouin's solution is used initially as a mordant for subsequent staining steps. Nuclei are then stained with Weigert's hematoxylin. The one-step trichrome stain (either green or blue) is then applied to differentially stain for muscle and collagen. Phosphotungstic acid favors red staining of muscle and cytoplasm. Tungstate ions are taken up by collagen, which reacts with the connective tissue fiber stain, coloring the collagen green or blue, depending on the stain used. Sections are then differentiated using 0.5% acetic acid. Most tissue will contain an internal quality control, but appendix, fallopian tube, uterus or small intestine may be used.

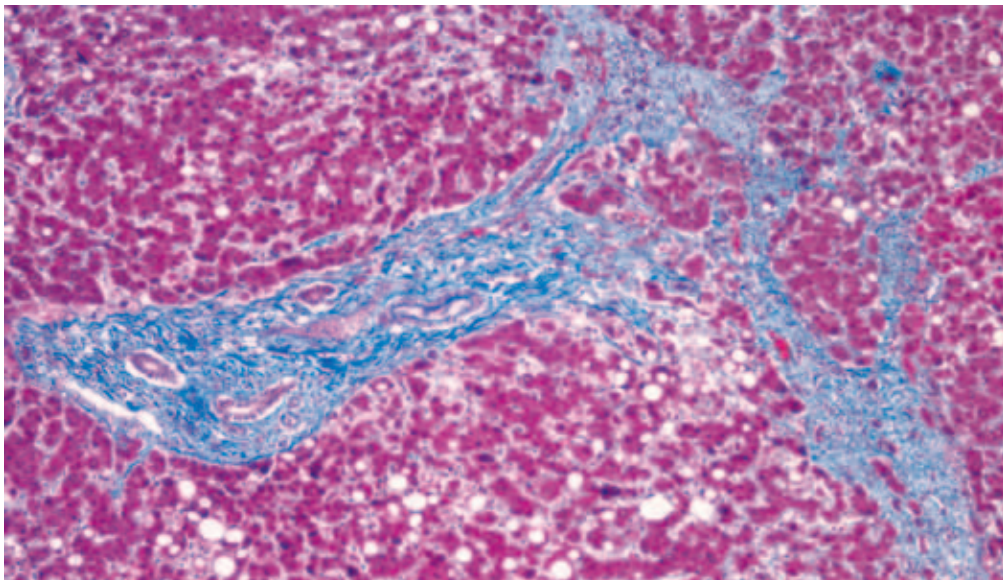


Figure 6. Gomori's trichrome stain is used to identify collagen in liver and kidney tissue specimens. (DakoCytomation Artisan).

#### Results

Feature	Visualization
Muscle fibers, cytoplasm	Red
Collagen	Green or blue
Nuclei	Black

#### Technical Considerations

- Viable Bouin's solution used at the correct temperature will ensure optimal staining.
- Intensity of staining may be controlled by increasing/decreasing incubation time in trichrome solution.

### PTAH

#### Clinical Application

Although trichrome techniques will demonstrate muscle fibers, PTAH, or phosphotungstic acid-hematoxylin, is preferred for demonstrating cross-striations of skeletal muscle, which may be lost in certain muscle diseases (Figure 7).

#### Chemistry

Collagen and muscle fibers are demonstrated using a tungsten mordant provided by the phosphotungstic acid. This mordant binds hematein and stains selective tissue components blue, while the phosphotungstic acid is believed to stain other tissue components a red-brown color. Tissue fixed in formalin is commonly post-fixed in Zenker's solution, which is thought to intensify staining reactions. A section of skeletal muscle tissue can be used for quality control.

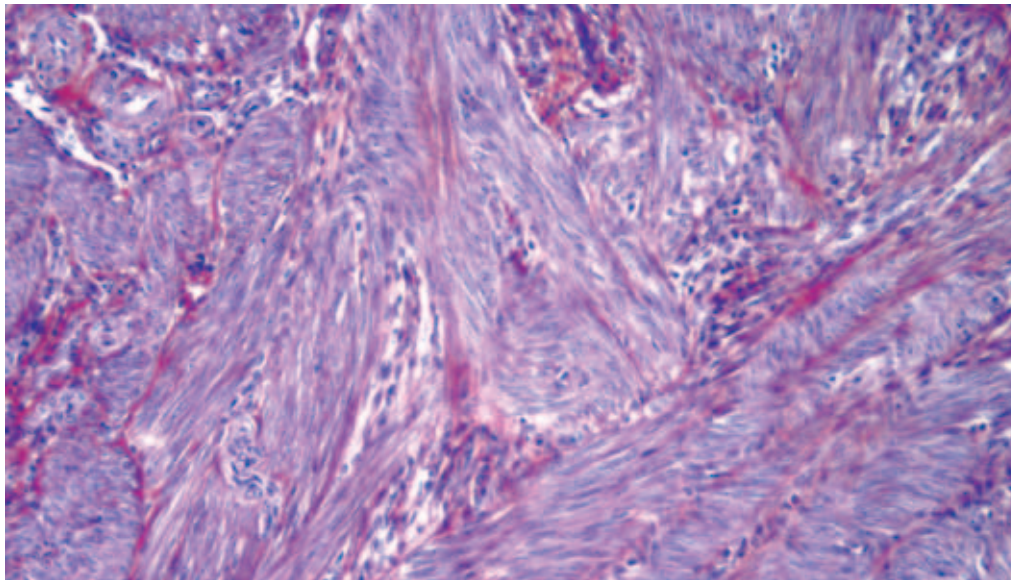


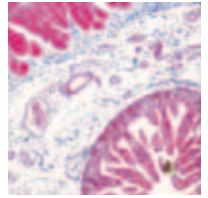
Figure 7. This PTAH stain demonstrates collagen (red-brown) and muscle fibers (blue).

#### Results

Features	Visualization
Muscle, cytoplasm, fibrin, keratin	Various shades of blue
Nuclei	Various shades of blue
Collagen	Red-brown

#### Technical Considerations

- Pale blue staining may indicate that the PTAH solution is over-oxidized and in need of replacement.
- Pale pink staining of collagen may indicate prolonged water and alcohol rinses.



### Modified Russel-Movat Pentachrome

#### Clinical Application

The Movat pentachrome method (Figure 8) offers a good technique for simultaneous demonstration of many entities such as muscle, elastic fibers, collagen/reticular fibers, ground substance and fibrinoid.

#### Chemistry

Acidic mucosubstances in the ground substance are stained by alcian blue and converted to insoluble monastral fast blue by exposure to alkaline alcohol. Iron hematoxylin (Weigert's) serves to stain nuclei and elastic fibers, which are subsequently differentiated by ferric chloride. Iodine contained within the working hematoxylin solution is removed by sodium thiosulfate. Crocein-scarlet-acid fuchsin effectively stains muscle, collagen and reticular fibers and overlies the monastral fast blue of the ground substance. Phosphotungstic acid subsequently differentiates connective tissue fibers and ground substance from muscle. With removal of crocein-scarlet-acid fuchsin from ground substance, monastral fast blue is again displayed. Acetic acid removes excess phosphotungstic acid. Collagen and reticular fibers are counterstained with an alcoholic saffron solution. Lung, skin and colon provide a source of quality control tissue.

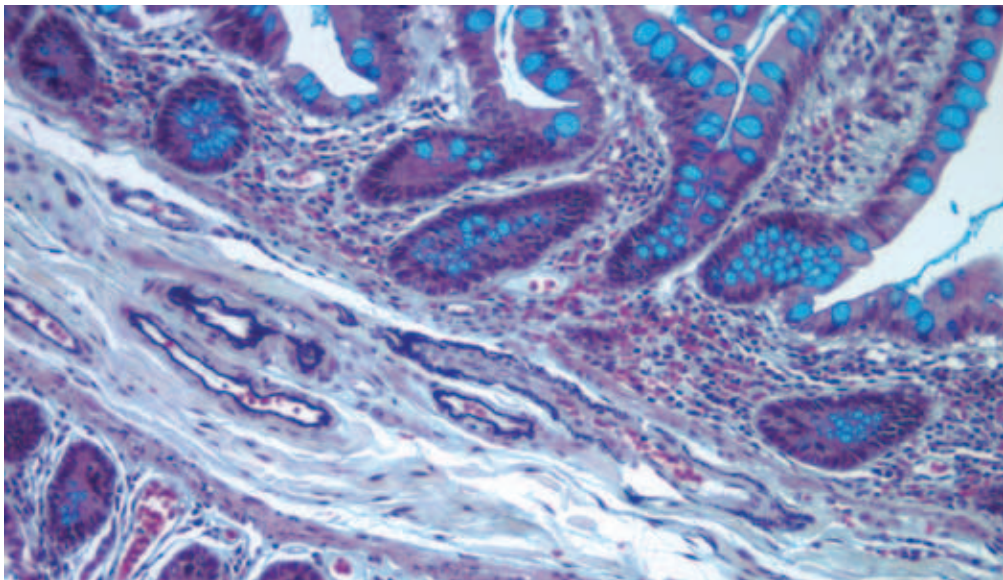


Figure 8. The modified Movat pentachrome stain demonstrates muscle, elastic fibers, collagen and reticular fibers in this small intestine specimen.

### Results

Features	Visualization
Nuclei, elastic fibers	Black
Collagen, reticular fibers	Yellow
Muscle	Red
Ground substance, mucin	Blue-green
Fibrinoid	Intense red

### Technical Considerations

- Complete removal of alkaline alcohol is critical for optimal subsequent staining.
- Differentiation in phosphotungstic acid should be monitored until collagen, reticular fibers are pale pink, and ground substance becomes bluish.

## Lipids

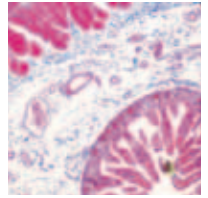
Lipids are classified as simple, compound and derived. Lipids occur in cells either as microscopic droplets or bound to other tissue elements. Staining of simple lipids with Sudan and oil red O dyes will be discussed here.

### Clinical Application

Abnormal deposition of fat may develop because of injury and form fat emboli, which may dislodge, relocate and cause loss of function or death. Liposarcomas may be differentiated from other tumor types using lipid-staining techniques. Degenerative changes in myelin and cell membranes may exude fat droplets demonstrated by these techniques.

### Chemistry

Simple lipids are demonstrated using oil red O and Sudan black B stains. These “staining” techniques demonstrate physical processes rather than chemical interactions displayed by most stains. The dye (oil red O or Sudan black B) is dissolved in a lipid solvent such as propylene glycol. Other fat solvents, such as isopropanol, may be used, but result in some lipid loss. Dye molecules are found to be more soluble in the cellular lipid than in the dye solvent and will migrate from the solvent into the tissue lipid, imparting a positive stain color to the tissue lipid. Tissue sections are then stained with an appropriate counterstain (hematoxylin/nuclear fast red). Tissue containing fat provide a source of quality control material.



### Results

#### Oil Red O

Feature	Visualization
Fat	Red
Nuclei	Blue

#### Sudan Black B

Feature	Visualization
Fat	Blue-black
Nuclei	Red

### Technical Considerations

- For demonstration of simple lipids, frozen sections must be used.
- Frozen sections may be unfixed or post-fixed in 10% neutral buffered formalin or formol-calcium.
- Tissue must not be exposed to fat solvents such as alcohols, acetone, xylene or paraffin.
- Aqueous mounting media must be used when coverslipping finished slides.

### References

1. Sheehan DC, Hrapchak BB. Theory and practice of histotechnology. 2<sup>nd</sup> ed. Columbus, OH: Batelle Press; 1980. p. 180–213.
2. Carson FL. Histotechnology: a self-instructional text. 2<sup>nd</sup> ed. Chicago: American Society of Clinical Pathologists Press; 1996. p. 131–56.
3. Luna LG. Histopathologic methods and color atlas of special stains and tissue artifacts. Downer's Grove, IL: Johnson Printers; 1992. p. 399–479.
4. Connective tissue and muscle morphology and staining. Bowie, MD: National Society for Histotechnology; 1990.
5. Bancroft J, Gamble M. Theory and practice of histological techniques. 5<sup>th</sup> ed. New York: Churchill Livingstone; 2002. p. 139–62, 201–30.



# Staining Methods: Carbohydrates and Amyloid

David A. Stanforth, BS

## Carbohydrates

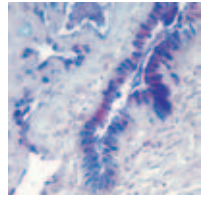
Carbohydrates are widely distributed in both plants and animals. They are often referred to as “starches” or “sugars” but can be divided into numerous subtypes based on their chemical structure. Over the years, diverse terminology has been used to describe and classify tissue carbohydrates. For the purposes of this chapter related to the staining of tissue carbohydrates, two main entities will be considered: glycogen and mucins (also known as mucosubstances).

Glycogen is a simple polysaccharide that is widely distributed throughout the body. It is found in greatest amounts in the liver, hair follicles, endometrial glands, vaginal and ectocervical epithelium, and cardiac and skeletal muscles.<sup>1</sup> Glycogen may have diagnostic significance in several types of tumors including carcinoma, mesothelioma and rhabdomyosarcoma.<sup>1-2</sup> Normal glycogen distribution patterns may be disrupted in diseases caused by carbohydrate metabolism enzyme deficiencies such as von Gierke’s disease and Pompe’s disease.<sup>1-2</sup>

Mucins are a large family of polypeptides that are secreted by a variety of epithelial and connective tissue cells.<sup>3</sup> They may function as lubricants or assist in cell adhesion or host defense.<sup>2</sup> The classification of mucins is complex but can, for purposes here, be simply divided into neutral and acid mucins. There are many subtypes of acid mucins based on their origin (epithelial vs. connective tissue) and molecular structure (sulfated, carboxylated). Mucins are produced by many tumors including carcinoma, liposarcoma and mesothelioma.<sup>1</sup> Abnormal systemic production of mucins is also found in diseases caused by enzyme deficiencies (Hurler disease, Schele disease, Hunter disease).<sup>1</sup>

## Amyloid

Amyloid is an intercellular material that is deposited in various tissues such as heart, muscle, skin, liver, spleen, kidneys and brain. It was originally classified as a carbohydrate, but amyloid is now classified based on the structure of its fibril subunit proteins.<sup>1</sup> Clinical amyloidosis can be classified based either on the underlying cause or by pattern of amyloid distribution. Amyloidosis may be associated with genetic predisposition, chronic inflammatory diseases, tumors or Alzheimer’s disease.<sup>4</sup> Sometimes the progression of the amyloidosis can be halted through treatment of the underlying condition, so early diagnosis is extremely important.



### Periodic Acid-Schiff (PAS)

#### Chemistry

The PAS reaction (Figure 1) demonstrates aldehyde groups formed by the oxidation of certain tissue carbohydrates and glycogen.<sup>2-3</sup> The oxidation of the tissue sections is performed using periodic acid. After oxidation, tissue sections are treated with Schiff reagent, a colorless mixture of basic fuchsin, HCl and sodium metabisulfite.<sup>1</sup> During incubation, basic fuchsin binds to the newly formed aldehyde groups in the tissue. Rinsing the sections in running water after the Schiff reagent incubation causes the bound basic fuchsin molecules to assume a pink to red color due to molecular changes.<sup>1</sup>

Several counterstains may then be used to visualize other tissue elements. Hematoxylin counterstaining is very commonly used to demonstrate cell nuclei, although other counterstains may also be used. Some older methods include treating the sections in a sulfurous rinse solution before the running water wash. This can serve to reduce background staining by removing excess Schiff reagent from the tissue.<sup>3</sup>

#### Clinical Applications

The PAS stain has a variety of clinical applications. It is most commonly used to evaluate glycogen deposits in the liver (See PAS with Diastase, below). Tumors of the bladder, kidney, liver, ovary, pancreas and lung may also contain glycogen granules of diagnostic significance.<sup>2</sup>

PAS is useful for the demonstration of basement membranes. These structures are normally present in many locations throughout the body. Abnormalities of the basement membranes revealed by PAS staining can aid in the diagnosis of several disorders. Evaluation of the basement membranes can also be used to measure the invasiveness of skin tumors.

PAS is often used for the demonstration of fungal infections due to the high carbohydrate content of the organism cell wall. When used for this purpose, a light green counterstain is usually preferred instead of hematoxylin.



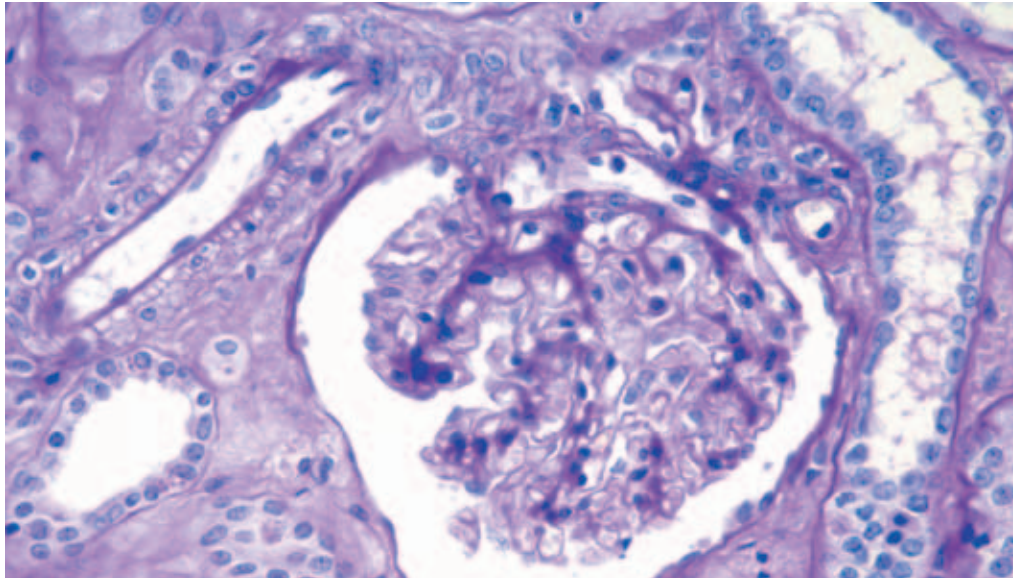


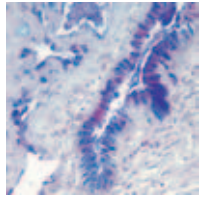
Figure 1. This PAS stain is used for the visualization of mucopolysaccharides and glycogen in renal tissue. Hematoxylin counterstains the nuclei blue. (Dako Autostainer Plus)

### Results

Feature	Visualization
Glycogen, fungi, basement membranes and certain mucosubstances	Pink to red
Nuclei	Blue, if counterstained with hematoxylin
Other tissue elements	Green, if counterstained with light green

### Technical Considerations

- Increasing or decreasing the incubation time of either the periodic acid or the Schiff reagent can increase or decrease the staining intensity. Incubation times should be optimized to obtain the desired result. Extending the wash time in running water may also increase the staining intensity.
- Schiff reagent is stored in the refrigerator so it is important to allow the reagent to come to room temperature before use. Failure to do so may result in weak staining. It is also important to store Schiff reagent in a tightly closed container when not in use so that the solution remains potent and stable.



### PAS with Diastase

#### Chemistry

Diastase is used in combination with the PAS stain to specifically identify glycogen granules.<sup>2-3</sup> Diastase is a malt extract that contains  $\alpha$  and  $\beta$ -amylase enzymes.<sup>2</sup> These enzymes can depolymerize glycogen into smaller sugars which are washed out of the tissue section after the enzyme treatment. Typically two serial sections are processed in parallel. One section is treated with a buffered diastase solution and the other is treated with buffer alone. Both sections are then washed and stained with the PAS reaction.

After PAS staining, the sections are compared under the microscope. Areas that are PAS-positive in the untreated section but PAS-negative in the treated section are assumed to be glycogen.<sup>3</sup> PAS staining that is present in both sections is due to the presence of other PAS-positive tissue elements that are not broken down by the diastase.

#### Clinical Applications

PAS with diastase (Figure 2) is used to stain and differentiate glycogen from other PAS-positive tissue elements. The distribution of glycogen deposits in the liver can aid in the diagnosis of several enzyme deficiencies.<sup>3</sup> PAS with diastase may also be used to distinguish glycogen granules from other granules in several types of tumors.<sup>2</sup>

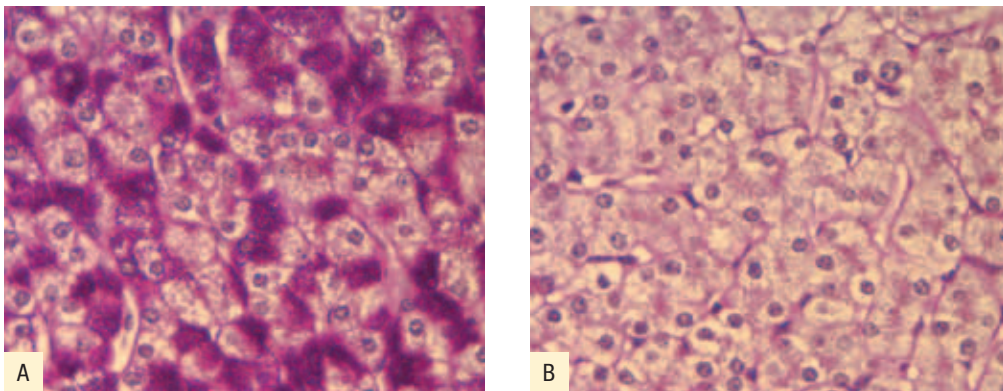


Figure 2. PAS with diastase (A) differentiates glycogen from other PAS-positive tissue elements (B). (Dako Autostainer Plus)

### Results

Feature	Visualization
Diastase-treated sections: Glycogen, fungi, basement membranes and certain mucosubstances	Pink to red
Untreated sections: Fungi, basement membranes and certain mucosubstances	Pink to red
Nuclei	Blue, if counterstained with hematoxylin

### Technical Considerations

- The diastase digestion step should be performed with solutions that have been preheated to 37° C for one hour prior to use. The strength of the diastase solution should be optimized to give complete glycogen digestion. Concentrations (w/v) of 0.1% – 1.0% are commonly used. The diastase should be dissolved in a phosphate buffer with a pH of around 6.0 for maximum effectiveness. Diastase dissolved in water may not give adequate performance.
- All the suggestions mentioned above for troubleshooting the PAS stain can also be used for PAS with diastase.

## Mucicarmine

### Chemistry

The mucicarmin stain (Figure 3) contains carmine (a red dye) bound in solution to aluminum. It is prepared as a concentrated stock solution and diluted to working strength just before use. It is believed that the aluminum acts as a mordant by binding to the acid groups of the mucin. This binding causes the carmine dye, which is carried along with the aluminum, to impart a deep pink or red color to the mucin.<sup>1,3</sup> Cell nuclei are usually stained with hematoxylin and the remaining tissue elements are counterstained with metanil yellow.

### Clinical Applications

Mucicarmin is used to demonstrate acidic mucins secreted by cells of epithelial origin.<sup>1,3</sup> It can also be used to stain the capsule of the *Cryptococcus* organism.

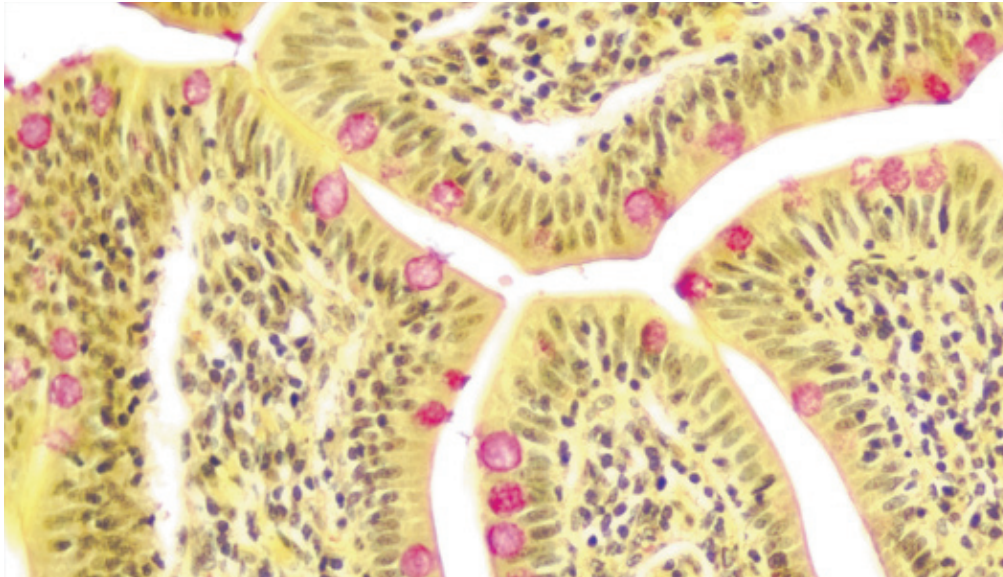
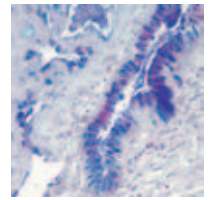


Figure 3. This mucicarmine stain is used for visualization of neutral epithelial mucins in small intestine. The mucins are stained rose to red, nuclei are blue/black, and other tissue elements are yellow. (DakoCytomation Artisan)

### Results

Feature	Visualization
Mucins	Deep rose to red
Nuclei	Blue or black, depending on the hematoxylin used
Other tissue elements	Yellow
Cryptococcus capsule	Deep rose to red

### Technical Considerations

The working mucicarmine solution should be made just prior to use and discarded after the procedure. Increase the mucicarmine incubation time for darker staining. The incubation times for the hematoxylin and metanil yellow can be optimized to obtain the desired color balance.

## Alcian Blue

### Chemistry

Alcian blue is a water soluble dye that derives its blue color from the copper in the molecule.<sup>2-3</sup> It is a basic dye and, therefore, has an affinity for tissue elements containing anionic groups such as acid mucins and other acidic carbohydrate moieties.<sup>3</sup> Alcian blue does not bind to DNA because of steric hindrance between the potential reactive groups and the large dye molecule.<sup>2</sup>

## Special Stains

Alcian blue can be used as a comprehensive acid mucin stain at pH 2.5 (Figure 4A). Alcian blue solutions of different pH will selectively stain subgroups of acid mucins. Alcian blue solutions of varying electrolyte concentrations can be used to further identify acid mucin subtypes (Figure 4B). Enzyme digestion procedures may also be used prior to staining in order to increase the staining specificity for the various subtypes.

Nuclear fast red is commonly used as a counterstain. Alcian blue may also be combined with PAS stain for the demonstration of both neutral and acid mucins (See Alcian Blue/PAS, below).

### Clinical Applications

Alcian blue is used for the demonstration of acid mucins, which can be produced by several types of epithelial and connective tissue tumors.<sup>2</sup> Acid mucins also play a role in collagen diseases and in the early stages of atherosclerosis.<sup>3</sup> The versatility of alcian blue staining methods is a valuable tool for the evaluation of the various acid mucins.

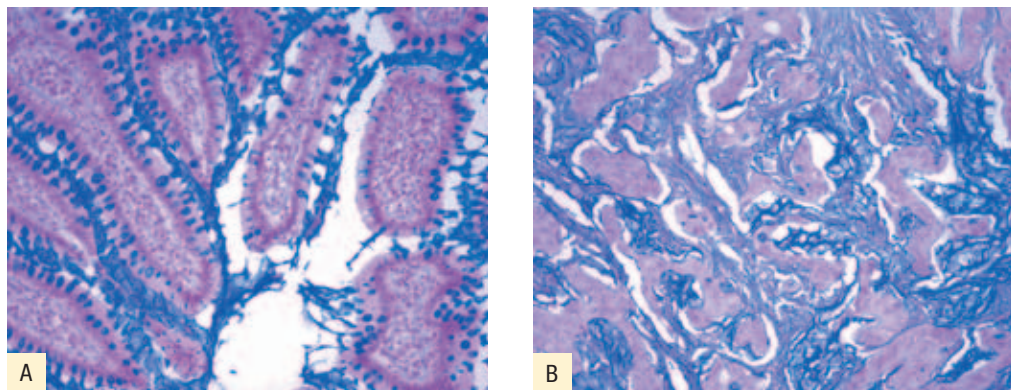


Figure 4. A) With the alcian blue stain, carboxylated and some weakly sulfated acid mucins appear blue at pH 2.5; B) At pH 1.0, weakly and strongly sulfated acid mucins appear blue. (Dako Autostainer Plus)

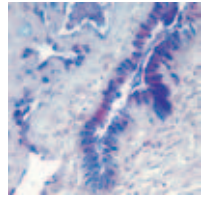
### Results

Feature	Visualization
pH 2.5 Carboxylated and some weakly sulfated acid mucins	Blue
pH 1.0 Weakly and strongly sulfated acid mucins	Blue
Nuclei	Red to pink
Other tissue elements	Pale pink

### Technical Considerations

The incubation times for alcian blue and nuclear fast red can be optimized to achieve the desired results. Longer incubation times lead to darker staining. The nuclear fast red should be well-mixed before use to assure good results. It is important to carefully follow





the instructions for the preparation of the alcian blue and pretreatment enzyme solutions. This will ensure the specific demonstration of the various acid mucins.

### Alcian Blue/PAS

#### Chemistry

Alcian blue and PAS can be combined to demonstrate both neutral and acid mucins (Figure 5). It is believed that staining the acid mucins first with alcian blue makes them nonreactive with the PAS stain that follows. Since only the neutral mucins will stain with PAS, a clear color distinction can be made between the neutral and acid mucins.<sup>2</sup> The procedures are carried out serially beginning with alcian blue. PAS staining follows and usually includes a light hematoxylin counterstain.

#### Clinical Applications

The combination of alcian blue and PAS offers a comprehensive method to evaluate the distribution of the various mucins, glycogen and other PAS-positive tissue elements.

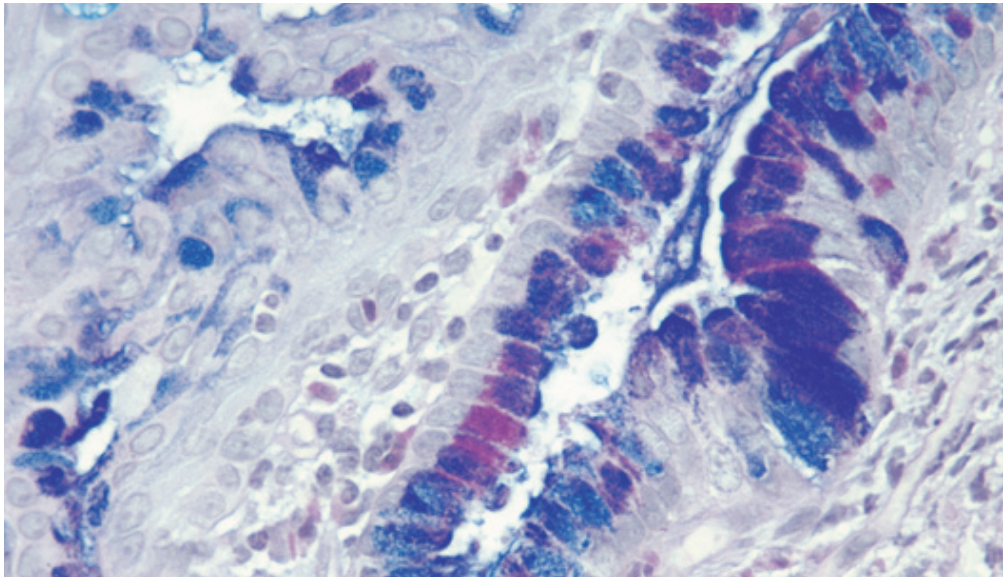


Figure 5. Alcian blue imparts a blue color to the acid mucins and other carboxylated/sulfated acid mucosubstances in this cervical tissue. PAS is then used to stain basement membranes, glycogen and neutral mucosubstances pink. (Dako Autostainer Plus)

### Results

Feature	Visualization
Acid mucins	Blue
Neutral mucins and other PAS-positive tissue elements	Pink to red
Mixtures of acid and neutral mucins	Bluish to reddish purple

### Technical Considerations

All the suggestions mentioned above for troubleshooting the PAS and alcian blue stains can also be used for this combined method. It is important to use a light hematoxylin counterstain so that it can be distinguished from the alcian blue staining.

## Colloidal Iron

### Chemistry

It is known that acid mucins can bind colloidal ferric ions under low-pH conditions.<sup>1-3</sup> These bound ferric ions can then be demonstrated using the Prussian blue reaction, which involves treating the sections with a solution of potassium ferrocyanide. This causes the formation of ferric ferrocyanide, a dark blue pigment, at the site of the reaction.<sup>1-3</sup>

Nuclear fast red can be used as a counterstain for the demonstration of acid mucins. The colloidal iron method may also be combined with the PAS stain for the demonstration of both neutral and acid mucins. In this case, the hematoxylin counterstain is eliminated.

### Clinical Applications

This method is most commonly used in place of the alcian blue/PAS stain. The main advantage is that the colloidal iron technique (Figure 6) is more sensitive when staining for acid mucins that may present in small amounts, such as in some mesotheliomas.<sup>2</sup> It should be noted however that the colloidal iron technique does not have the same histochemical specificity of some of the alcian blue methods.<sup>3</sup>




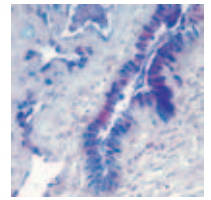


Figure 6. Modified Mowry's colloidal iron with Van Gieson counterstain demonstrates acid mucins (dark blue) in this skin section.

### Results

Feature	Visualization
Acid mucins	Dark blue
Neutral mucins and other PAS-positive tissue elements	Pink to red if stained with PAS
Mixtures of acid and neutral mucins	Bluish to reddish purple
Nuclei	Pink to red if stained with nuclear fast red

### Technical Considerations

- All the suggestions mentioned above for troubleshooting the PAS stain can be used with this method. The incubation time for the potassium ferrocyanide should be optimized to eliminate nonspecific background staining.
- It may be necessary to rule out nonspecific staining of tissue hemosiderin by running a control slide with the potassium ferrocyanide alone. Any blue staining on that slide should be excluded during the analysis of the colloidal iron slide.<sup>2</sup>

## Congo Red

### Chemistry

Congo red is a dye with a selective affinity for amyloid (Figure 7). It is believed that the linear shape of the molecule is responsible for its ability to bind the  $\beta$ -pleated sheet structure of the amyloid.<sup>3-4</sup> The binding is thought to be through non-polar hydrogen bonds. The staining methods used favor the formation of these bonds over electrochemical bonds

## Special Stains

that may bind the Congo red to other tissue elements.<sup>4</sup> A combination of high pH and high sodium in the staining solution favors selective binding of the dye and the amyloid.

The binding arrangement between the dye and the amyloid produces a unique effect (apple-green birefringence) when the stained tissue is observed with polarized light.<sup>3-4</sup> The presence of apple-green birefringence has become the most reliable diagnostic feature of amyloid.<sup>1,3-4</sup> Hematoxylin is usually the counterstain of choice for the Congo red stain.

### Clinical Applications

Amyloid deposits are formed in tissues spontaneously or in association with a wide range of disease conditions.<sup>4</sup> The deposits are intercellular and may become large enough to cause damage to surrounding tissues. Depending on the type of underlying disease, amyloid deposits may form in muscle, heart, skin, tongue, liver, spleen, kidneys or adrenals.

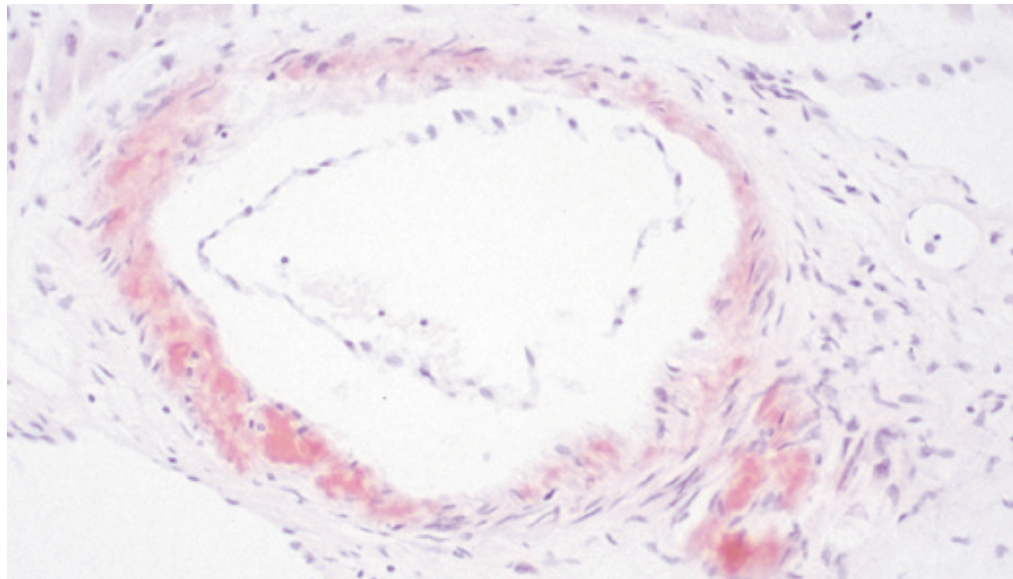
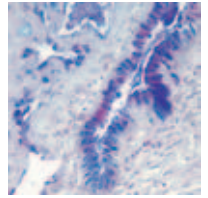


Figure 7. This Congo red stain is used to detect amyloid in heart tissue. (Autostainer Plus)

### Results

Feature	Visualization
Amyloid	Pink to red (apple-green with polarized light)
Nuclei	Blue



### Technical Considerations

- The high sodium concentration of the staining solution is important in order to obtain specific staining. Some methods may use sodium hydroxide (1% w/v) either before or after staining to reduce background.
- Tissue sections should be used within six months of cutting. Cut sections stored for longer periods may exhibit weak or negative staining.<sup>3</sup> Sections should be cut at 7–10 microns in order to observe the correct apple-green birefringence. Thinner sections will show a bluish or reddish birefringence while thicker sections will appear yellowish under polarized light.<sup>1–2,4</sup>

### References

1. National Society for Histotechnology. Carbohydrate stain reference manual. Lanham, MD: National Society for Histotechnology; 1989.
2. Bancroft JD, Stevens A, editors. Theory and practice of histological techniques. 4<sup>th</sup> ed. London: Churchill Livingstone; 1996. p. 173–211.
3. Sheehan DC, Hrapchak BB. Theory and practice of histotechnology. 2<sup>nd</sup> ed. St. Louis, MO: The C.V. Mosby Company; 1980. p. 159–79.
4. Bancroft JD, Stevens A, editors. Theory and practice of histological techniques. 4<sup>th</sup> ed. London: Churchill Livingstone; 1996. p. 151–72.

## Staining Methods: Microorganisms

Sonja Wulff

Since the goal in performing many special stains is detection and identification of microscopic, pathogenic organisms, any basic discussion of special staining techniques requires some knowledge of relevant pathogens. These pathogens fall into three primary classifications: bacteria, fungi and protozoans.

### Bacteria

Bacteria are tiny, single-celled organisms that range in size from 0.2  $\mu\text{m}$  to 10  $\mu\text{m}$ . They are protected by a cell wall but have no nuclear membrane enclosing their genetic material. Though the cell walls of pathogenic bacteria share a basic chemical composition — cross-linked chains of amino sugars, glucosamine and muramic acid — about 100 types of cell wall structures allow diagnostic differentiation of these organisms into major groups.

### Mycobacteria

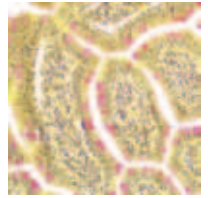
A family of bacteria with particular diagnostic relevance is Mycobacteria. This family includes *Mycobacterium tuberculosis*, the causative agent of tuberculosis, which kills roughly two million people worldwide each year. These organisms are nonmotile rod-shaped bacteria that typically bundle together to form cordlike groups. The unique structure and composition of their cell walls is an excellent diagnostic differentiator.

### Helicobacter

Another common target for special staining procedures is *Helicobacter pylori*, a spiral-shaped bacterium implicated in gastric inflammation, peptic ulcers and gastric cancer. *H. pylori* produce an adhesive that allows attachment to stomach epithelial cells and a urease that provides protection from the highly acidic environment in the stomach.

### Spirochetes

Spirochetes are readily recognized by their distinct helical shape and motility. Members of the genus *Treponema* live in the mouth, digestive tract and genital areas of humans and other animals and are the causative agent of syphilis and yaws, a contagious tropical disease. Members of the genus *Borrelia* (3–20  $\mu\text{m}$ ) are the causative agents of tick-borne Lyme disease and relapsing fever. Members of the genus *Leptospira* are the causative agent of leptospirosis, which can cause kidney damage, meningitis, liver failure, and respiratory distress if left untreated.



### Fungi

Fungi are a diverse family of both single-celled and multicellular organisms with a distinct membrane-bound nucleus and a cell wall composed of chitin. For nutrition, they absorb small organic molecules from the surrounding environment, and they reproduce by releasing spores that allow wide geographic distribution. They are responsible for a number of human diseases.

The most common fungal disease in humans is histoplasmosis, which is caused by the organism, *Histoplasma capsulatum*. Reproductive spores are inhaled from the soil and lodge in the lungs, sometimes creating lesions that become calcified. Three other types of fungi can cause similar respiratory diseases — *Pneumocystis carinii*, *Coccidioides immitis* and *Blastomyces dermatitidis*. *P. carinii* is a fungus known to cause a fatal pneumonia in immunocompromised individuals. Infection with *C. immitis* typically doesn't result in symptoms, though chronic disease can occur when spherules of the organism collect in localized pockets in the lungs. Roughly half the patients infected with *B. dermatitidis* present with flu-like symptoms, and those who fail to recover can develop chronic pulmonary infection or systemic disease affecting the skin, bones and genitourinary tract.

The other major group of fungi involved in human disease is yeast. *Candida albicans* is a normal resident of the gastrointestinal tract, mouth and vaginal area, and is typically kept in check by the body's normal flora. However, in the absence of the normal flora or in immunocompromised individuals, *C. albicans* can proliferate and cause disease systemically, orally and vaginally. Another member of the yeast family, called *Cryptococcus neoformans*, can infect the lungs, though patients typically don't develop symptoms, except in the case of immunocompromised individuals.

### Protozoans

Protozoans are single-celled organisms that lack a cell wall. This family includes Amoebae and Flagellates. Amoebae are noted for their peculiar movement in which the cell projects membrane extensions of the cytoplasm, called pseudopodia, into the environment. The cytoplasm then flows into the area of the pseudopodium. Flagellates are protozoans that move by long flagella, which resemble tails. Pathogenic members of this family include *Entamoeba histolytica*, which causes amoebic dysentery; *Naegleria fowleri*, which causes encephalitis; *Toxoplasma gondii*, which affects the central nervous system; *Trichomonas vaginalis*, a sexually transmitted protozoan that causes a vaginal infection; and *Trypanosoma gambiense*, which causes African sleeping sickness.

A discussion of common microorganism stains follows.

## Gram Stain

### Clinical Applications

The Gram stain (Figure 1) has diagnostic significance as a common differentiator of the microorganism that cause bacterial infections, such as meningitis, pneumonia, bacteriuria, gonorrhea and infections of the brain, lung, abdomen, pelvis and wounds. Examples of Gram-positive bacteria include *Clostridium botulinum*, *Clostridium tetani*, *Staphylococcus aureus* and *Corynebacterium diphtheriae*. Gram-negative bacteria include *Salmonella*, *Shigella dysenteriae*, *Escherichia coli* and *Pseudomonas aeruginosa*.

### Chemistry

Bacteria can be classified as either Gram-positive or Gram-negative, based on the composition of the cell wall and its permeability to dyes or stains. The cell walls of both Gram-positive and Gram-negative organisms contain peptidoglycan, but Gram-positive bacteria have thicker cell walls, while Gram-negative bacteria have an additional layer of lipopolysaccharide outside the cell wall. These structural differences affect the way these bacteria retain dye complexes. With the Gram stain, all bacteria take up a crystal violet-iodine complex. However, upon decolorization, Gram-positive bacteria retain the dye complex, while Gram-negative bacteria do not. Subsequent counterstaining allows visualization of Gram-negative organisms.

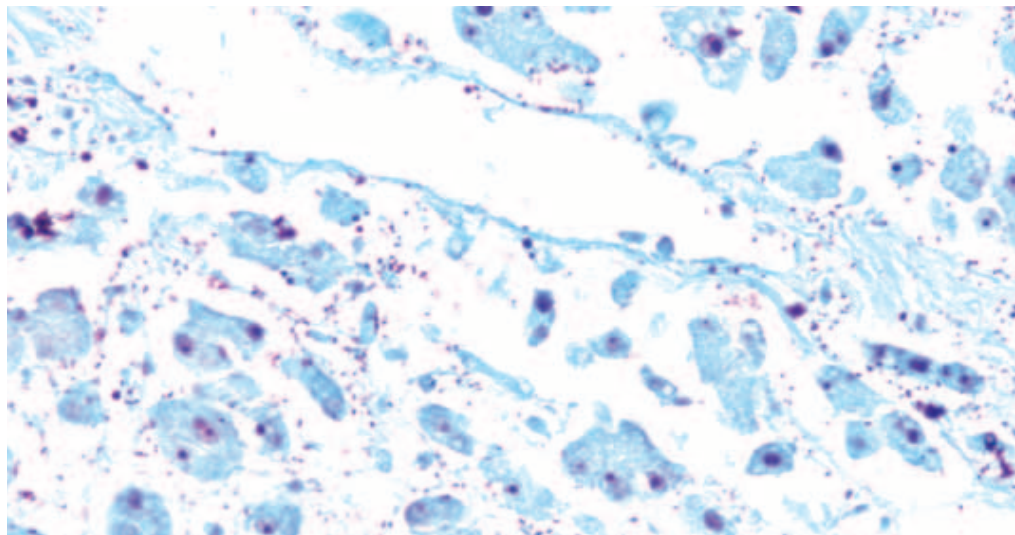
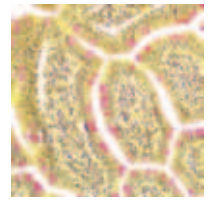


Figure 1. The modified Gram stain, performed here on placental tissue, uses crystal violet to mark the Gram-positive bacteria blue, and decolorization changes the Gram-negative bacteria red. Twort's stain imparts a blue-green background for easier visualization. (DakoCytomation Artisan)

### Results

Feature	Visualization
Gram-positive bacteria	Blue or violet
Gram-negative bacteria	Red





### Technical Considerations

- If crystals appear, change the alcohol. If there is water in the alcohol, crystals can get trapped under the membrane, causing masking of the bacteria.
- Some asbestos can stain, looking like small dumbbells.

## Acid-Fast Bacteria Stain

### Clinical Applications

The acid-fast bacteria (AFB) stain (Figure 2) is key to diagnosing *Mycobacterium* infection. Members of this family include *Mycobacterium tuberculosis* and *Mycobacterium leprae*, the causative agents of tuberculosis and leprosy, respectively.

### Chemistry

*Mycobacteria* produce a distinctive group of waxy substances, called mycolic acids, that covalently link to peptidoglycan in the bacterial cell wall. Mycolic acids make standard staining procedures difficult, but they also uniquely withstand alcohol decolorization following staining with hot carbol-fuchsin. This property, known as acid fast, is an excellent diagnostic differentiator.

The Fite acid-fast bacteria stain is the method of choice for detecting *M. leprae*.

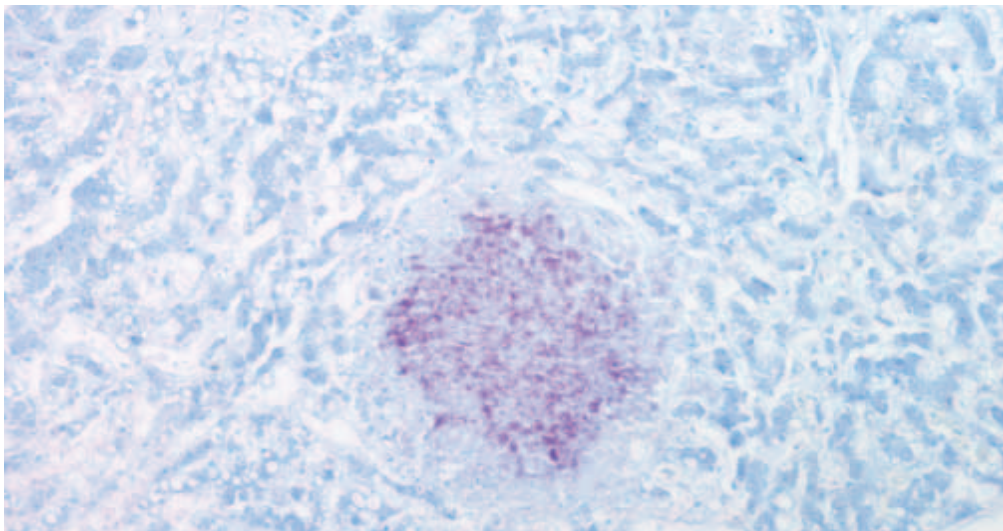


Figure 2. The acid-fast bacteria stain, performed here on lung tissue, allows visualization of bacteria belonging to the *Mycobacterium* genus. Application of carbol-fuchsin stains acid-fast bacteria fuchsia, while a methylene blue counterstain imparts a blue color to all background tissue elements. (DakoCytomation Artisan)

### Results

Feature	Visualization
Acid-fast bacteria	Bright red or fuschia
Background	Light blue



### Technical Considerations

- If you overstain with the methylene blue counterstain, differentiate in 95% alcohol to desired contrast or decolorize in acid alcohol and restain.
- Use distilled or deionized water for rinsing prior to carbol fuchsin step. Do not use tap water, as it could contain acid-fast organisms and, thus, result in a false-positive slide.
- Viable organisms stain uniformly; staining of non-viable organisms yields a beaded appearance.

## Grocott's Methenamine Silver Stain

### Clinical Applications

The Grocott's methenamine silver (GMS) stain (Figure 3) is useful to identify a variety of pathogenic fungi, including *Aspergillus fumigatus*, *Blastomyces dermatitidis*, *Candida albicans*, *Coccidioides immitis*, *Cryptococcus neoformans*, *Histoplasma capsulatum*, *Nocardia asteroides*, *Pneumocystis carinii* and *Sporothrix schenckii*.

### Chemistry

Methenamine silver methods rely on the oxidation of carbohydrates within the tissue/fungus to form aldehyde groups. These groups will directly act to reduce silver ions from the methenamine silver solution to visible metallic silver. Sodium thiosulfate is used to remove any unreduced silver.

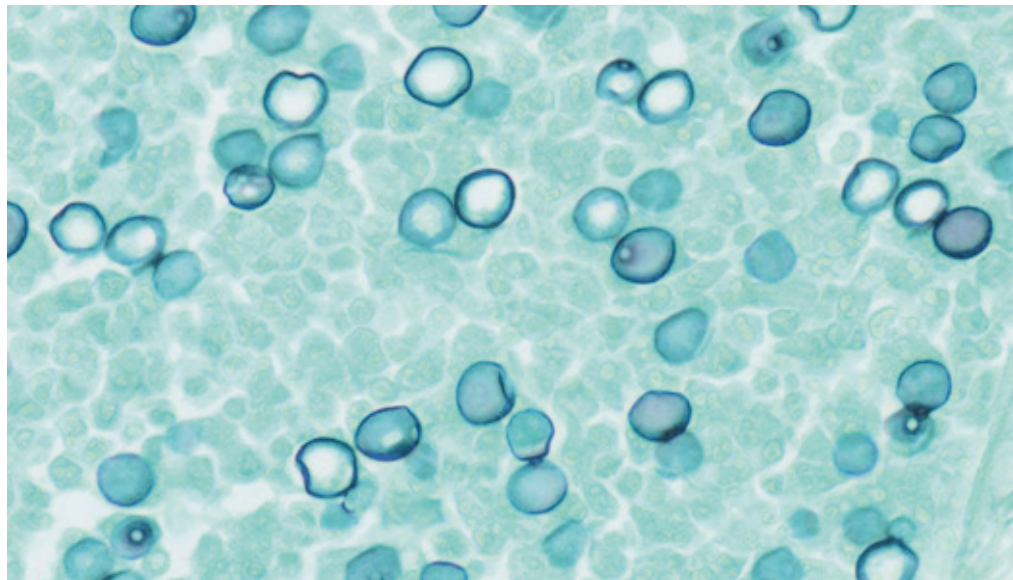
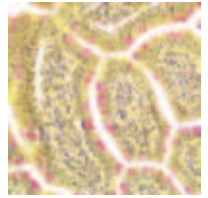


Figure 3. With the modified Grocott's methanamine silver method, *P. carinii* stains black, while other tissue elements are bluish green. (DakoAutostainer Plus)



### Results

Feature	Visualization
Fungi	Black
Background	Light green

### Technical Considerations

- Use non-coated slides to prevent ionic binding of the silver solution. Ionic binding will appear as a metallic haze over the entire slide. Some gelatins can also cause this effect.
- The chromic acid component is sensitive to oxidation. Keep solution free of contamination and change when the orange color turns more to a copper brown.
- Reduce incubation times and temperatures when staining cytology specimens.
- Nonspecific staining of reticulin fibers, red blood cells and other tissue structures may result if incubation in the methenamine-silver solution is too extensive.

## Warthin-Starry Stain

### Clinical Applications

The Warthin-Starry stain (Figure 4) is useful in identifying Spirochetes and some other bacteria, such as *H. pylori* and two causative agents of cat scratch disease, *Bartonella henselae* and *Afipia felis*.

### Chemistry

The Warthin-Starry stain relies on the ability of certain bacteria to bind silver ions from solution. Subsequent addition of a reducing agent then converts this bound silver to visible metallic silver. In the Warthin-Starry stain, the tissue is sensitized prior to application of the silver complex. An aqueous silver nitrate solution combined with the reducing agent, hydroquinone, is applied, and a silver diamine complex is generated.

Two other common stains — Dieterle and Steiner & Steiner — rely on a similar mechanism of action. They also can be used to identify these microorganisms.

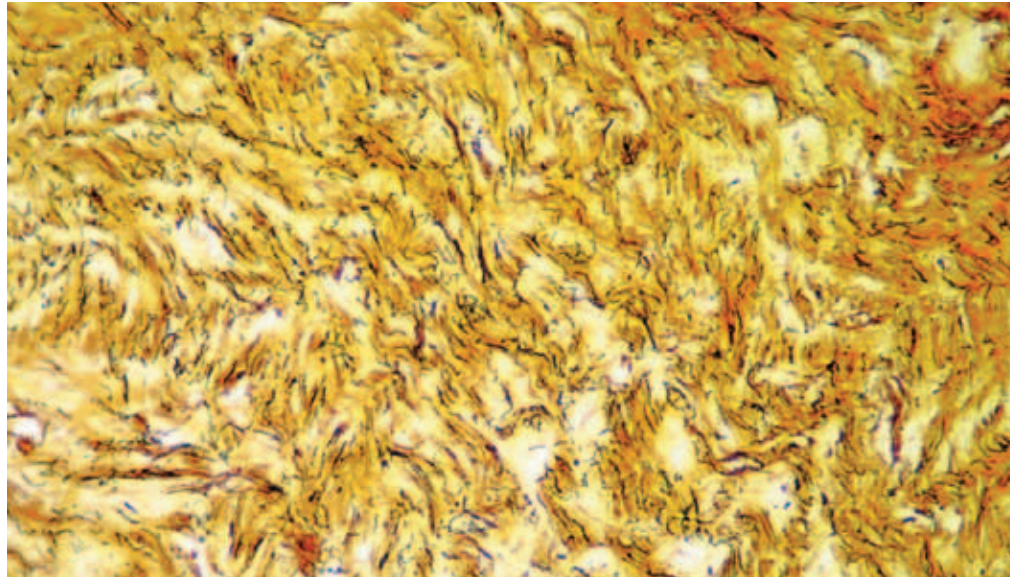


Figure 4. The Warthin-Starry stain is used for the visualization of Spirochetes. The microorganisms appear black, while the background is pale yellow to light brown. (DakoCytomation Artisan)

### Results

Feature	Visualization
Bacteria	Black
Background	Yellow to light brown

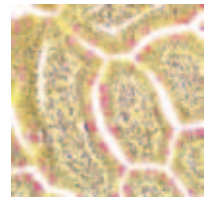
### Technical Considerations

- Use non-coated slides to prevent ionic binding of the silver solution.
- Formalin fixation is optimal.
- Pretreatment with uranyl nitrate can improve staining.
- The hydroquinone reagent (developer) is sensitive to light and oxidation; store according to manufacturer's recommendations.

## Alcian Yellow/Toluidine Blue Stain

### Clinical Applications

The alcian yellow/toluidine blue (AY/TB) stain (Figure 5) is a common way of screening patient specimens for *H. pylori*. *H. pylori* is a spiral-shaped bacterium implicated in gastric inflammation, peptic ulcers and gastric cancer.



### Chemistry

*H. pylori* can be difficult to detect because it is usually embedded in mucus lining the stomach. Mucus is neutral and, thus, will not stain directly with basic dyes. With the AY/TB stain, the mucus is treated with periodic acid to oxidize the hydroxyls to aldehydes. When natural alcian yellow dye is used, the tissue is treated with sodium metabisulfite to yield highly acidic mucins, which then stain with alcian yellow. When synthetic alcian yellow dye is used, the mucins stain readily after periodic acid oxidation with the dye. Washing with acetic acid removes excess dye. In both cases, toluidine blue stains the bacteria, so that they stand out clearly against the yellow mucin.

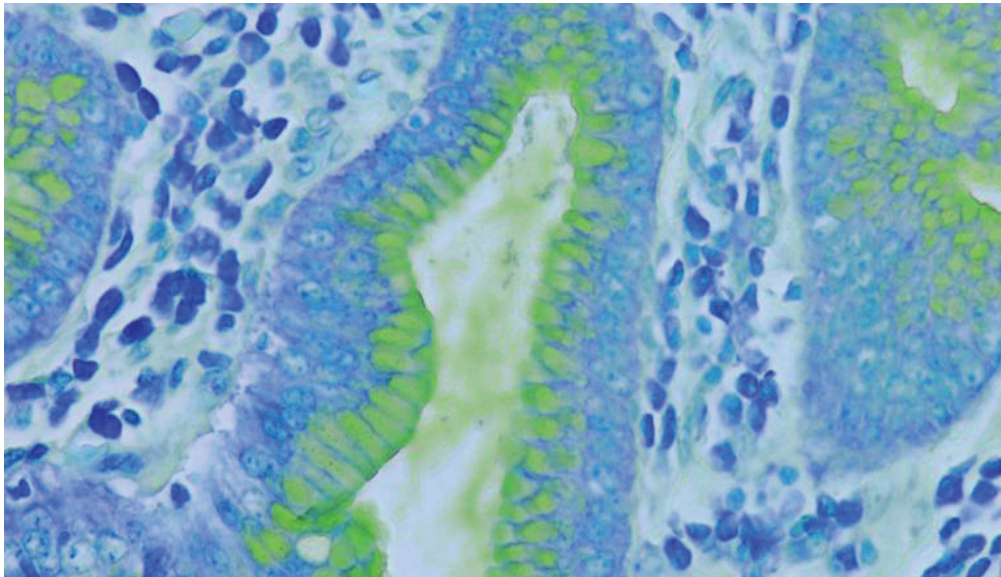


Figure 5. Alcian yellow/toluidine blue stain is used here to visualize *H. pylori* in a gastric biopsy. (DakoCytomation Artisan)

### Results

Feature	Visualization
<i>H. pylori</i>	Blue
Mucin	Yellow
Background	Pale blue

### Technical Considerations

- Fixation can determine the hue of the yellow. Depending on fixation time and fixative choice, the mucins will vary between greenish and yellowish hues.
- If the periodic acid has aged considerably, its efficacy is reduced, and the results may vary. Thus, storing the reagents properly and using them within shelf life is critical to performance of reactions within the stain.



## Giemsa Stain

### Clinical Applications

Another screening method for detecting *H. pylori* in tissue sections is the Giemsa stain (Figure 6), which can also be used to demonstrate the Gram-negative bacteria, Rickettsia, and the protozoan, *Toxoplasma gondii*. For a discussion of other applications of this versatile stain, see Chapter 5, Nucleus and Cytoplasm.

### Chemistry

The Giemsa stain belongs to a family of stains known as the Romanowsky stains. These stains use neutral dyes generated by combining a basic dye, such as methylene blue, and an acidic dye, such as eosin. Differentiation with a weak acid solution is required.




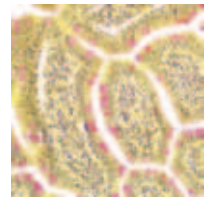
Figure 6. This gastric biopsy stained with Giemsa demonstrates *H. pylori*. (Dako Autostainer Plus)

### Results

Feature	Visualization
<i>H. pylori</i>	Dark blue
Other bacteria	Blue
Nucleus	Dark blue
Cytoplasm	Pink

### Technical Considerations

- The pH of the solutions and buffers can be critical for a successful stain.
- The Giemsa working solution does not tend to be stable, so it should be made fresh each time the stain is performed.



## Periodic Acid-Schiff-Green Stain

### Clinical Applications

The periodic acid-Schiff-Green (PAS-green) stain (Figure 7), which has a wide range of applications, can be used to aid in diagnosis of fungal infections. For a discussion of other applications for this stain, see Chapter 7, Carbohydrates and Amyloid.

### Chemistry

Periodic acid oxidizes polysaccharides in the fungal cell wall to aldehydes, which in turn react with Schiff reagent to result in visualization. With fungal infection, a light green counterstain is typically used.

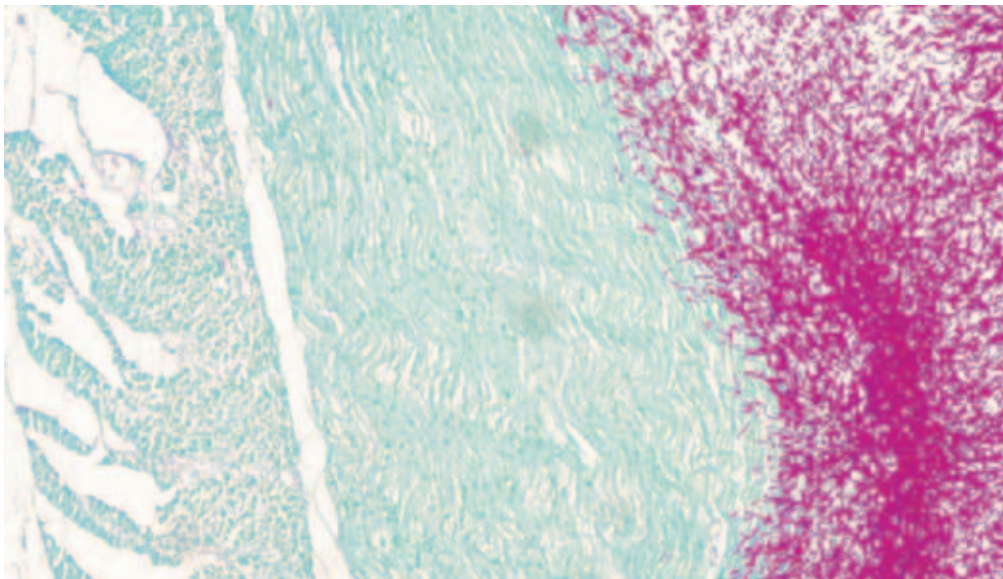


Figure 7. The PAS-green stain, shown here on an esophagus specimen, is most commonly used for visualization of fungi. (DakoCytomation Artisan)

### Results

Feature	Visualization
Fungi	Pink to fuschia
Background	Light green

### Technical Considerations

- Keep reagents stored to manufacturer's specifications. They can be sensitive to temperature changes, which can decrease their strength.
- If the Schiff reagent has been contaminated or exposed to air, it will appear pink. You should filter or replace the Schiff reagent if you notice weakening reactivity.
- In addition, the periodic acid can weaken. Keep periodic acid fresh to ensure proper oxidation of the aldehyde groups.

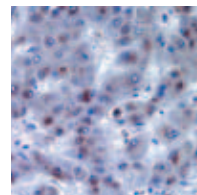


### References

1. Campbell NA. *Biology*. 3rd ed. Redwood City, CA: The Benjamin/Cummings Publishing Company, Inc.; 1993.
2. Carson FL. *Histotechnology: a self-instructional text*. 2nd ed. Chicago: ASCP Press; 1997.
3. Cheles M. The indisputable value of silver. *Connection* 2003; 7: 18.
4. Disease information. 2003; Available at: <http://www.cdc.gov/ncidod/dbmd/diseaseinfo>. Accessed October 9, 2003.
5. Hashimoto T, Birch WX. Gram stain. 1996; Available at: <http://www.meddean.luc.edu/lumen/DeptWebs/microbio/med/gram/gram-strn.htm>. Accessed February 19, 2004.
6. Leung k, Gibbon KJ. A rapid staining method for *Helicobacter pylori* in gastric biopsies. *Journal of Histotechnology* 1996; 19(2): 131.
7. Perry JJ, Staley JT. *Microbiology: dynamics and diversity*. Fort Worth, TX: Saunder College Publishing; 1997.
8. Tuberculosis. 2002; Available at: <http://www.who.int/mediacentre/factsheets/fs104/en>. Accessed February 20, 2004.

### Acknowledgment

Special thanks to Jamie Holliday, HT (ASCP), DakoCytomation Technical Support Group, for Technical Considerations included in this chapter.



## Staining Methods: Pigments and Minerals

Susie Smith, BS, HTL (ASCP), Laurie J. Hafer, PhD

### Pigments

Pigments play an important part in the diagnosis of diseases and conditions such as gout, kidney and gallbladder stones, jaundice, melanomas, Albinism, hemorrhage and tuberculosis. In tissue sections, the term pigment refers to a material that has color and can be seen without a microscope. It can be either normal or pathological. Pigments are identified either by their color, size and shape or by chemical testing. For example, if the chemical test normally gives a blue color, and it is applied to a yellow pigment, the results will be a green color. Pigments can be separated into three categories: artifact, exogenous and endogenous (Table 1). The endogenous pigments are described in this chapter.

Table 1. Common Pigments

Artifact	Exogenous	Endogenous
Formalin	Iron	Melanin
Mercury	Carbon	Hemosiderin
Potassium dichromate	Lipochromes	Lipofuscin
		Urates
		Bile

### Melanin

#### Clinical Applications

The most recognized pigment is melanin. Melanin, a brown or black pigment derived from metabolism and not directly associated with blood, is normally found in skin cells (melanocytes), hair follicles, eyes (iris) and areas of the embryonic brain. It is also found in patches in the arachnoid membrane that lines the brain and in the melanosis coli of the gut. The distribution and amount of melanin is what accounts for the wide variety of skin, hair and eye colors. Pathologically, melanin is found in conditions of malignant melanomas, Addison's disease, metabolism disturbances and benign nevus tumors.

#### Chemistry

Melanin possesses the uncanny ability to bind silver from silver solutions and reduce it directly to metallic silver. It is also almost completely insoluble in organic solvents because of its tight bond with proteins. Melanin also is a strong reducing agent. Special staining techniques for melanin are varied in approach and can be simple or complex. Schmorl's reaction is a simple technique that uses melanin to reduce ferric iron ( $Fe^{3+}$ ) to ferrous

## Special Stains

iron ( $\text{Fe}^{2+}$ ). The ferrous iron then combines with ferricyanide to form ferrous ferricyanide, also known as Turnbull's blue. More complex techniques use silver nitrate solutions. The Fontana-Masson method for melanin and the Warthin-Starry method for melanin are two such methods. The Warthin-Starry method is further described. Silver nitrate solution first is applied to the tissue section. Melanin reduces the silver to metallic silver. A developing solution is applied to remove unreduced silver and to tone the metallic silver. The final step is application of nuclear fast red counterstain. As with all the special staining techniques for melanin, this reaction is not melanin-specific and may stain other elements, such as argentaffin, chromaffin and some lipofuscins.

### Results

Feature	Visualization
Melanin	Black
Nuclei	Pink
Cytoplasm	Yellow to orange

### Technical Considerations

Melanin can be bleached over time by strong oxidizers. The melanin bleach method can also be used to remove melanin. Lipofuscins are also removed from the tissue when using this technique. For the melanin bleach method to be effective, it may be necessary to oxidize in 0.25% potassium permanganate solution an additional 5 to 20 minutes. Tissue sections are then briefly introduced to 5% oxalic acid, which bleaches the melanin. Tissues can remain immersed until the sections become clear. Sections should be washed for at least one minute to remove traces of oxalic acid. This wash step should be done gently so the tissue is not loosened from the slide.

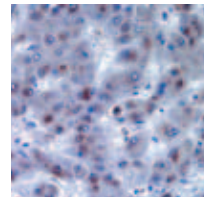
## Hemosiderin

### Clinical Applications

Hemosiderin, a blood-derived pigment, is a crystalline aggregate of proteins involved in iron storage. Some of the pathological conditions involving hemosiderin are hemorrhage, hemolytic anemia, metabolic iron disturbances, liver fibrosis, toxins, cirrhosis, heart failure and diabetes mellitus.

### Chemistry

Appearing yellow to golden brown in unstained tissue, hemosiderin is insoluble in alkalis and soluble in strong acid solutions. Fixation in formalin alters hemosiderin so that it can be solubilized slowly in weak acids. In Mallory's and Perl's methods for iron, the ferric ion in tissue binds with ferrocyanide in solution forming ferric ferrocyanide, otherwise known as Prussian blue. Because ferric iron in hemoglobin is tightly bound to proteins, it is first necessary to use acid to release it from the protein complex. A combination of hydrochloric acid (releasing solution) and potassium ferrocyanide (binding solution) is able to release



and stain the ferric iron at the same time. Nuclear fast red is the typical counterstain for these stains.

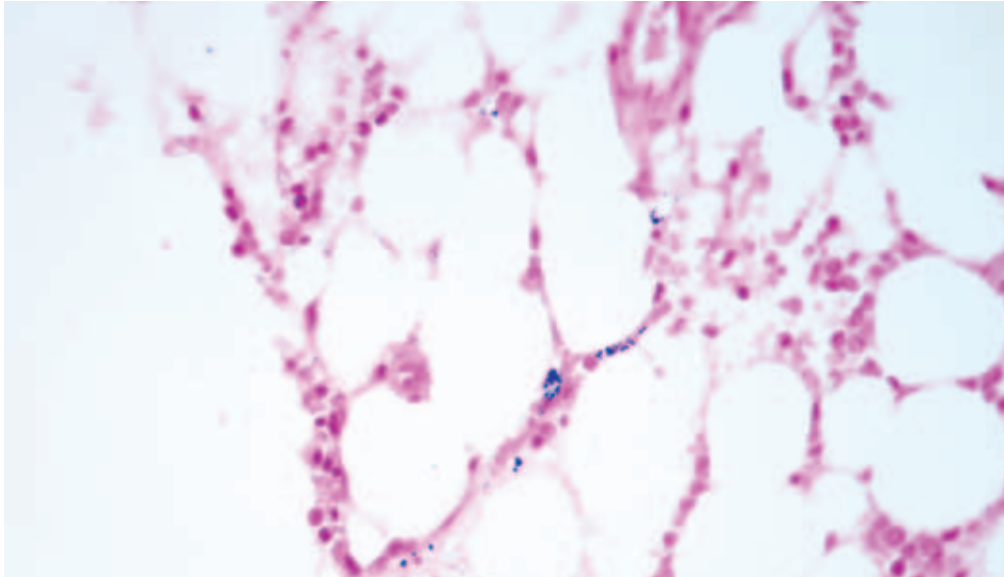


Figure 1. Perl's method demonstrates iron in this bone marrow specimen. (DakoCytomation Artisan)

### Results

Feature	Visualization
Ferric iron	Blue
Nuclei, cytoplasm	Red

### Technical Considerations

Be careful not to overstain with the nuclear fast red, because it may mask iron pigment that is delicately stained.

### Lipofuscin

#### Clinical Applications

Lipofuscin, a yellow-brown to reddish-brown pigment, is found in many parts of the body including bone marrow, adrenal, kidney, liver, heart, testis, ovary, cervix, brain and spinal cord. Lipofuscin is formed by the slow oxidation of lipids and lipoproteins. It has been nicknamed the “wear-and-tear” pigment because large accumulations of lipofuscin are found in people of advanced age. When identified using special staining techniques, lipofuscin can be found in a variety of colors, shapes and sizes. The physical properties of lipofuscin are dependent upon the length of time that the original lipid or lipoprotein has undergone oxidation. It is recommended that more than one special staining technique be performed to confirm the presence of lipofuscin. Pathologically, lipofuscin is present in some lipid storage diseases, such as Batten's disease, and can be found at the edges of cerebral hemorrhage or infarcts.

### Chemistry

Special staining techniques for lipofuscin include oil red O, Sudan black B, Gomori's aldehyde fuchsin (Figure 2), methyl green basophilia, periodic acid-Schiff and Fontana-Masson. Each stain has its own unique approach to staining lipofuscin. Gomori's aldehyde fuchsin will be further discussed. Tissue sections are oxidized in potassium permanganate. Oxalic acid is then applied to bleach the tissue section. The tissue is then stained with aldehyde fuchsin, which binds to the lipofuscin. After rinsing in alcohol, the tissue section is counterstained with tartrazine.

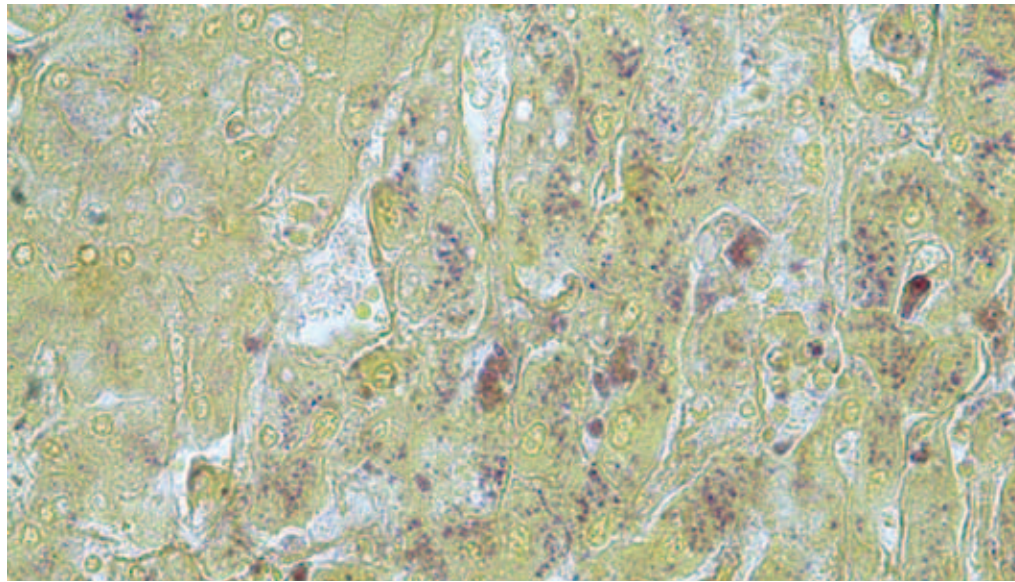


Figure 2. This Gomori's aldehyde fuchsin stain demonstrates lipofuscin in liver tissue.

### Results

Feature	Visualization
Lipofuscin	Purple
Background	Yellow

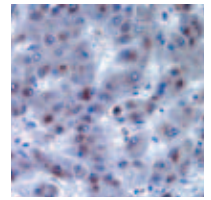
### Technical Considerations

It is important to note that results will vary based on the state of oxidation.

### Urates

#### Clinical Applications

Nucleic acid metabolism creates uric acid, which is normally excreted. Urate is the form of uric acid that circulates in the bloodstream. Crystallized urate is in the form of monosodium urate. The color of crystalline urate is characteristically yellow but can vary from colorless to brown, depending on the thickness of the crystals. Pathologically, crystallization or increased urate in the blood predisposes a patient to gout, poor kidney function, kidney stones and arthritis. In other diseases, such as leukemia, urates can ultimately be



deposited in the kidneys. This happens because an extremely high number of cells are destroyed, resulting in nucleic acid metabolism and generation of uric acid.

### Chemistry

In tissue, uric acid crystals are present as sodium urate, which is soluble in aqueous solutions and slightly soluble in weak alcoholic solutions. The fixative of choice is 95% alcohol, which prevents the dissolution of the urates. Sodium urate crystals can be visualized on a hematoxylin & eosin (H&E) stained slide under a polarized light with a red compensator. The urates will demonstrate a negative yellow or blue birefringence, based on the alignment of the urate crystals. A special staining technique, Gomori's methenamine-silver method, can also be used to identify urate crystals in tissue sections. Tissue sections are placed into a methenamine-silver solution. Urates, like melanin, can bind silver from silver solutions and reduce it directly to metallic silver. After reducing the silver, sodium thiosulfate is used to remove the unreduced silver from the tissue sections. The section is then counterstained with light green.

### Results

Feature	Visualization
Urates	Black
Background	Green

### Technical Considerations

It is important to note that an alcoholic fixative must be used in order to preserve the urates.

## Bile

### Clinical Applications

Red blood cells have an average lifespan of 120 days. At the end of their lifespan, red blood cells degrade, and most of their components are recycled and used in the production of new red blood cells. One waste product of this degradation is biliverdin. Biliverdin is transported to the liver, where it is further reduced to bilirubin. Bilirubin is then removed from circulation in the blood and is secreted as a component of bile. Bile is transported to the gallbladder and ultimately to the colon for excretion from the body.

Biliverdin and bilirubin are considered bile pigments. Bile pigments can vary in color from yellowish-brown to green. Pathologically, excess bile pigment is seen in patients with gallstones, sepsis, liver degeneration, congenital liver enzyme disorders and liver tumors. When there is an obstruction in the flow of bile to the gallbladder or colon, these pigments can be observed in hepatocytes, or liver cells, as yellow-brown globules, and clinically, the patient will appear jaundiced. The obstruction can be within the liver or in organs other than the liver. For example, a carcinoma at the head of the pancreas can also cause an obstruction in the flow of bile and an accumulation of bile pigments. Histologically, it



## Special Stains

is important to distinguish bile pigments from lipofuscin, particularly in cases of possible sepsis in liver transplant patients.

### Chemistry

The most reliable and reproducible special staining technique for demonstrating bile pigments is Hall's technique. In this technique bilirubin is easily oxidized to biliverdin in a solution of ferric chloride and trichloroacetic acid. The tissue section is then counterstained with Van Gieson's solution. Only bile and bile pigments in the liver are detected using this special staining technique. To demonstrate bile pigments in other locations outside the liver, such as hemorrhage, either the Gmelin technique or Stein's stain should be used. These techniques have generally been considered unreliable, difficult to interpret, lack permanency of results and will not be described further.

### Results

Feature	Visualization
Bilirubin oxidized to biliverdin	Emerald green to olive
Muscle, cytoplasm	Yellow
Collagen	Red

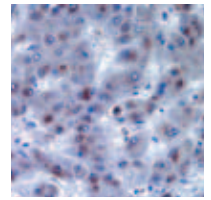
### Technical Considerations

Small amounts of bile pigments are lost during routine tissue processing and staining because of their slight solubility in organic solvents. Large deposits of bile pigments, however, can resist these processing procedures. It is recommended that two control sections should be processed with the test section. Both sections should be oxidized with Fouchet's reagent, but only one should be counterstained with Van Gieson's. The second section should not be counterstained. A more reliable result can be obtained if fresh Fouchet's reagent is used each time.

## Minerals

Minerals are important for the growth, development and function of the human body. They serve as catalytic agents in many of the biological reactions in the body, including muscle responses, neuronal signaling, hormone production, digestion and nutrient processing. Because the body cannot produce minerals, humans acquire them from the food that they eat.

The most common minerals that can be demonstrated by special staining techniques are calcium, iron and copper. The previous section detailing identification of hemosiderin encompasses detection of iron. Calcium and copper special staining techniques will be further discussed.



### Calcium

#### Clinical Applications

Calcium is an insoluble mineral that is part of the normal composition of bones, teeth and nails. It is one of the most important minerals used by the human body, participating in such vital functions as blood clotting, neuronal signaling, muscle response and heart rhythm. Calcium deficiency cannot be identified using special staining techniques. Pathologically, abnormal deposits of calcium can be found associated with necrotic tissue areas in cases of tuberculosis, atherosclerosis, kidney calcinosis, sarcoidosis, hyperparathyroidism and kidney stones.

#### Chemistry

There are two well-known special staining techniques for demonstrating calcium deposits: Von Kossa and alizarin red S. The Von Kossa calcium stain is an indirect method for identifying calcium in tissue. The primary calcium salts in tissue are calcium phosphate and calcium carbonate. In this technique, silver is substituted for calcium and is then reduced to metallic silver with sunlight. The metallic silver marks the location of the calcium in the tissue.

The stain of choice for identification of calcium is the alizarin red S calcium stain. This dye binds specifically to calcium at a pH of 4.2. The calcium-alizarin red S complex that results is birefringent.

#### Results

Feature	Visualization
Calcium deposits	Orange-red

#### Technical Considerations

During the staining technique, the reaction must be monitored microscopically to ensure that diffusion artifact does not occur. Tissues preserved in non-acidic fixatives are the best for demonstrating calcium deposits.

### Copper

#### Clinical Applications

Most enzyme activity in the human body is dependent on the trace mineral, copper. Copper deficiency is extremely rare. Pathologically, the accumulation of copper is associated with Wilson's disease, which is a rare congenital disease. Copper deposition can be demonstrated in the liver, brain and cornea in patients with Wilson's disease. Primary biliary cirrhosis and other liver disorders are also likely to demonstrate copper accumulations.

### Chemistry

The special staining technique of choice for demonstrating copper is the rhodanine method (Figure 3). The rhodanine dye binds to copper or copper-associated proteins. Tissue sections are then counterstained in hematoxylin.

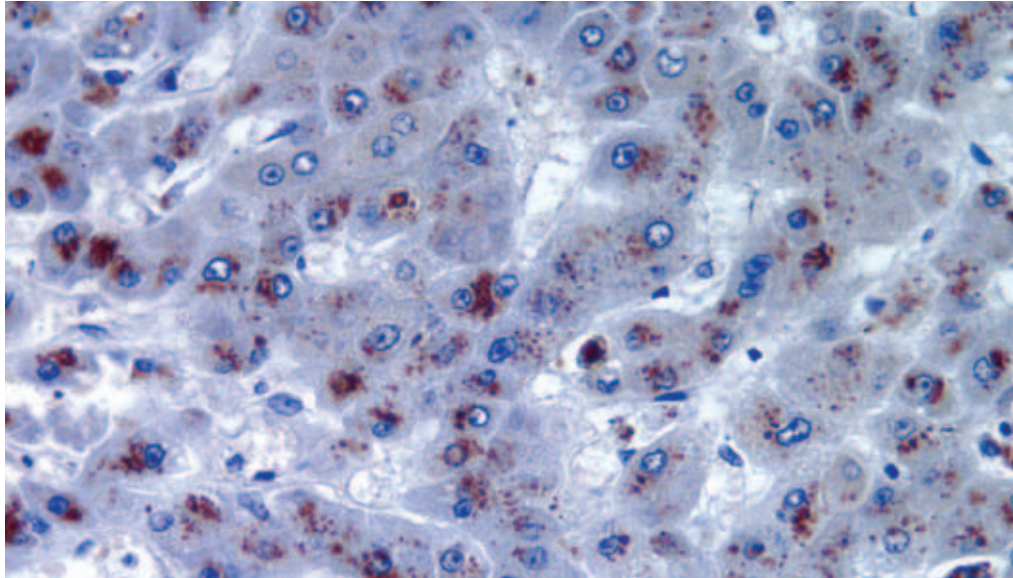


Figure 3. The special staining technique of choice for demonstrating copper is the rhodanine method, shown here on a liver section.

### Results

Feature	Visualization
Copper and copper-associated protein	Red to orange-red
Nuclei	Blue

### Technical Considerations

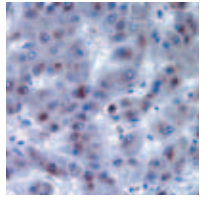
After coverslipping, fading of the stained copper may occur if the copper concentration within the tissue is low. If the tissue section is overstained with hematoxylin, the copper may be difficult to visualize. A weak-staining reaction may be resolved by the use of tissue sections thicker than 6  $\mu\text{m}$ .

### References and Suggested Reading

1. Bancroft JD, Stevens A, editors. Theory and practice of histological techniques. 4th ed. New York: Churchill Livingstone; 1996.
2. Sheehan D, Hrapchak B. Theory and practice of histotechnology. St. Louis, MO: CV Mosby Company; 1973.
3. Lee GL. Histopathologic methods and color atlas of special stains and tissue artifacts. Gaithersburg, MD: American Histolabs Inc., Publications Division; 1992.

## Staining Methods: Pigments & Minerals

---



4. Prophet E, Mills B, Arrington J, Soblin L. Laboratory methods in histotechnology. Washington, DC: Armed Forces Institute of Pathology; 1992.
5. Carson FL. Histotechnology: a self-instructional text. 2<sup>nd</sup> ed. Chicago: American Society of Clinical Pathologists Press; 1996.

## Staining Methods: Nervous System

Susie Smith, BS, HTL (ASCP), Laurie J. Hafer, PhD

The nervous system of the human body has two branches, the central nervous system (CNS) and the peripheral nervous system (PNS). The CNS includes the brain and spinal cord; whereas the PNS is composed of all other nerve tissue. Special staining techniques for the CNS are divided into three groups: neurons, glial cells and myelin. The stains used for these three groups will be the focus of this chapter.

### Neurons

The neuron, or nerve cell, is the functional unit of the nervous system. It consists of a cell body, the axon and multiple projections, known as dendrites (See Chapter 2, Figure 4: Nerve Cell). The cell body contains the nucleus, a prominent nucleolus and cytoplasmic organelles, such as the Golgi apparatus, endoplasmic reticulum and mitochondria, which maintain the cell. Neurons do not divide; therefore, the nucleus of a neuron contains very active chromatin, and the nucleolus is condensed into a large prominent clump. The axon, also commonly known as the nerve fiber, acts as the long-range transmitter of impulses to other nerves or targets. The dendrites, or dendritic processes, are the impulse receivers, creating a continuous loop of impulse exchange between neurons, until the impulse reaches its target, such as a muscle. Though neurons contain the same cellular structures as other types of cells, they also have several unique cytoplasmic structures. Neurons contain neurofibrils, tubules and filaments that serve as the cytoskeleton for the cell. These fibrils and tubules help to transport the protein molecules from the endoplasmic reticulum in the main cell body of the neuron to the ends of the dendritic processes, which do not contain rough endoplasmic reticulum.

A cytoplasmic structure known as Nissl substance is of particular interest to the anatomic neuropathologist. Nissl substance is often referred to as Nissl bodies, Nissl granules, tigroid bodies or chromophil substance. Nissl substance is primarily composed of ribonucleic acid (RNA) and proteins and aggregates with the rough endoplasmic reticulum. These aggregates are involved in protein synthesis and cellular metabolism.

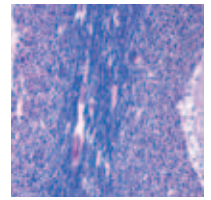
### Cresyl Violet Stain

#### Clinical Application

The cresyl violet stain is the most common Nissl substance stain. This stain is useful in identifying neurons in a tissue section and in assessing neuronal damage by demonstrating the loss of Nissl substance. Nissl substance is generally located in a random radial pattern surrounding the nucleus. Neuronal injury causes cell swelling, and Nissl substance is pushed away from the nucleus to the outer edges of the neuron. When severe neuronal

## Staining Methods: Nerve

---



damage has occurred, a complete loss of Nissl substance is seen. This is known as chromatolysis.

### Chemistry

Because of the high RNA content, Nissl substance can be selectively stained using basic aniline dyes such as azure, thionin and cresyl violet. Tissue sections are stained with cresyl violet and then differentiated in alcohol, until the background is colorless.

### Results

Feature	Visualization
Nissl substance	Blue to purple
Nuclear chromatin	Blue to purple
Background	Colorless

### Technical Considerations

Formalin is generally the preferred fixative, but other fixatives can also be used. The basic aniline dye will depend of the type of tissue fixation. For example, thionin is used with alcohol fixed tissue but does not stain particularly well on formalin-fixed tissue. The timing of the differentiation step can be adjusted so that only the Nissl substance or both the nuclei and Nissl substance are stained.

## Bielschowsky Method

### Clinical Application

Neurons and neurofibrils can be stained using several special staining techniques, including the Bodian, Holmes silver nitrate, and the Bielschowsky methods. The Bielschowsky method is particularly useful in the identification of neurofibrillary tangles and senile plaques, which are the hallmarks of Alzheimer's disease. Senile plaques, also called neuritic plaques, consist of an amyloid core surrounded by either axonal or dendritic processes. The Bielschowsky method will be further described.

### Chemistry

The tissue section is treated with silver nitrate and ammoniacal silver nitrate solutions. Silver is deposited on the neurofibrillary tangles and axonal or dendritic processes of senile plaques. This silver is then reduced to metallic silver with formalin. Sodium thiosulfate is used to remove the unreduced silver.



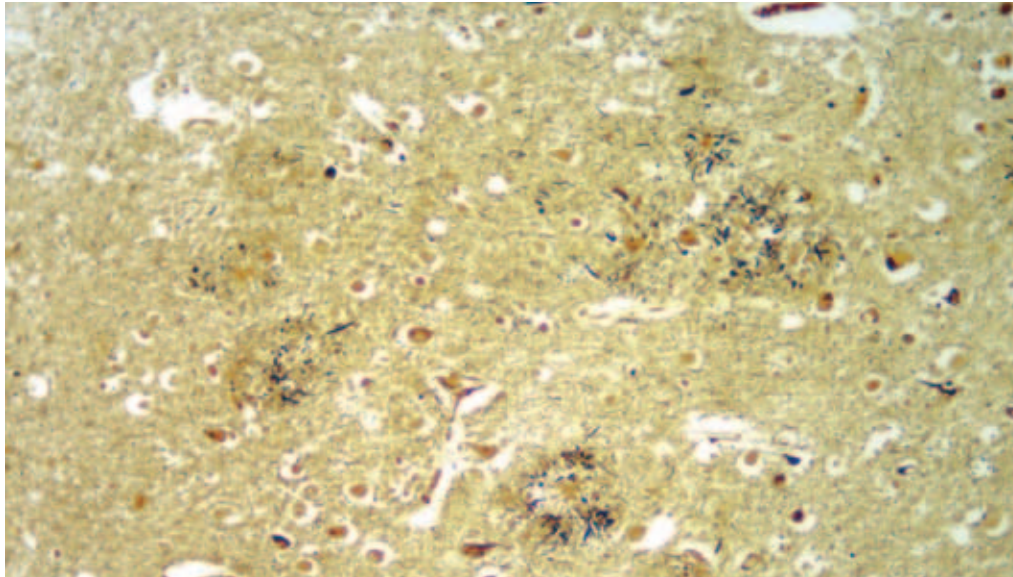


Figure 1. This modified Bielschowsky stain demonstrates senile plaques in the cerebrum.

### Results

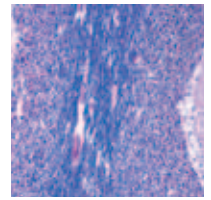
Feature	Visualization
Neurofibrillary tangles and senile plaques	Black
Background	Yellow to gold

### Technical Considerations

It is essential that acid-cleaned glassware and nonmetallic forceps are used during the staining process to avoid non-selective precipitation of silver. This special staining technique can be performed on both paraffin-embedded and frozen tissue sections.

### Glial Cells

Astrocytes, oligodendroglia, microglia and ependymal cells are the four types of glial cells. Astrocytes are star-shaped cells that act as a supporting network for neurons and distribute nutrition to them. Astrocytes protect the CNS following injury by repairing the damaged area with an area of proliferation or scar formation, known as gliosis. Oligodendroglia produce the myelin sheath that surrounds axons, and they also act as supporting cells for the neurons. Microglia are the phagocytic cells of the brain. They clean away debris from cell and tissue injury. Ependymal cells line walls of the spinal canal and the ventricles of the brain. These epithelial cells serve as a barrier between the cerebrospinal fluid and the nervous tissue. Special staining techniques for glial cells are rarely performed today, because immunohistochemical procedures have replaced them.



### Clinical Application

When the special staining techniques for glial cells are requested, astrocytes are generally the cells of interest. Injury and disease of the CNS associated with astrocytes, such as astrocytoma, can be demonstrated using a few techniques. The stains that can be used to identify glial cells are the phosphotungstic acid hematoxylin (PTAH) stain (Figure 1), Holzer method and Cajal stain. The PTAH stain is further discussed.

### Chemistry

Tissue sections are oxidized in potassium dichromate. Lugol's iodine is applied to remove the potassium dichromate from the tissue. The Lugol's iodine is removed from the tissue section with 95% ethanol. A second round of oxidation using potassium permanganate is performed. The section is then bleached with oxalic acid before being stained with the PTAH staining solution. This staining solution is a combination of a mordant and a dye, otherwise known as a lake. The solution has also been described as polychromatic because it imparts two different colors to the tissue section.

### Results

Feature	Visualization
Nuclei, myelin and glial cells	Blue
Cytoplasm	Pink or salmon

### Technical Considerations

The reagents used for this stain should be well-mixed and stored in well-sealed containers. The immunohistochemical staining technique utilizing Glial Fibrillary Acidic Protein (GFAP) has virtually eliminated the use of this stain.

## Myelin

Myelin is a complex, phospholipid-rich material that forms a protective sheath around the axon and insulates it from the surrounding extracellular space. Following routine processing, only neurokeratin, a proteolipid, remains in the tissue. Oligodendroglia produce the myelin sheath in the CNS. Diseases, such as multiple sclerosis, can cause a breakdown of the myelin sheaths. When axons are severed, they disintegrate, and the myelin sheath surrounding the severed axon degenerates as well. Loss of the myelin sheath is known as demyelination.

### Clinical Application

There are several stains for demonstrating myelin, all with different coloration. The one procedure that has been used successfully in laboratories for years is Luxol fast blue (LFB). Not only does LFB demonstrate myelin, but it also differentiates between the white and gray matter of the brain. Additionally, a tissue section can be stained with LFB and then treated with another stain. For example, LFB-PTAH stains for myelin and glial cells;

## Special Stains

LFB-Periodic Acid Schiff-hematoxylin is used to examine myelin, vascular pathways and cellular elements of the brain; LFB-oil red O demonstrates myelin and fat or lipids; and LFB-hematoxylin & eosin (LFB-H&E) is used to identify myelin and tissue architecture (Figure 2).

### Chemistry

The basic LFB staining technique takes advantage of a simple acid-base reaction and the formation of salt. Luxol fast blue is a sulfonated copper phthalocyanine dye. The tissue section is dyed with the Luxol fast blue staining solution and the base of myelin proteolipid such that the base the dye are exchanged, resulting in a dark blue precipitate. Excess dye is removed with 95% ethanol. The tissue section then differentiated in lithium carbonate, 70% ethanol, several times until the gray matter is colorless. The white matter will be blue to blue-green.

The use of one of the combination stains will result in colors that are appropriate for the secondary element(s) stained. The results listed below are appropriate for only Luxol fast blue.

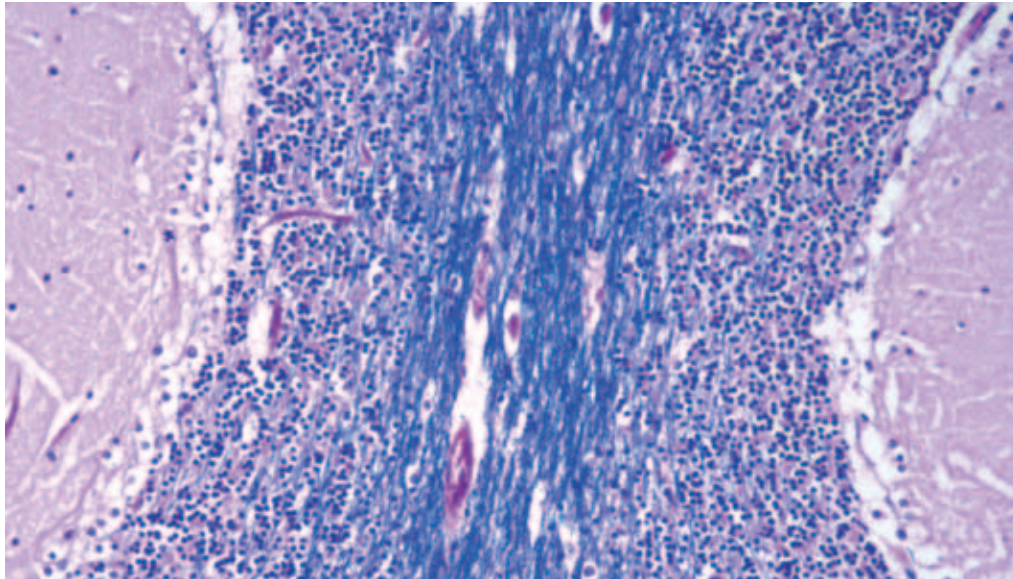
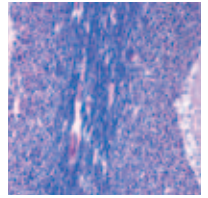


Figure 2. Luxol fast blue-H&E demonstrates myelin in this cerebellum section.

### Results

Feature	Visualization
Myelin, including phospholipids	Blue to blue-green
Background	Colorless



### Technical Considerations

Prior to application of the secondary stain, the gray and demyelinated white matter should be colorless and clearly distinguishable macroscopically from the blue to blue-green myelinated white matter. If the gray matter is not colorless, differentiation should be continued. The Luxol fast blue dye is alcohol-soluble, not water-soluble; therefore this solution should be kept in a well-sealed container during the staining technique and for storage.

### References and Suggested Reading

1. Carson FL. Histotechnology: a self-instructional text. 2nd ed. Chicago: ASCP Press; 1997.
2. Lee GL. Histopathological methods and color atlas of special stains and tissue artifacts. Gaithersburg, MD: American Histolabs Inc., Publications Division; 1992.
3. Prophet E, Mills B, Arrington J, Soblin L. Laboratory methods in histotechnology. Washington, DC; American Registry of Pathology; 1992.
4. Ross MH, Kaye GI, Pawlina W. Histology: a text and atlas. 4th ed. Philadelphia: Lippincott Williams & Wilkins; 2003.
5. Sheehan DC, Hrapchak BB. Theory and practice of histotechnology. 2nd ed. St. Louis, MO: The C.V. Mosby Company; 1980.

# Automation of Special Stains

David A. Stanforth, BS

## Overview

Automated immunohistochemistry, or IHC, staining has become prevalent over the past 10 years, and the trend toward automation has expanded in recent years to include special stains. Some of the same companies that have developed automated IHC staining platforms have realized the potential for automating special stains. Many platforms can be used to perform both IHC and special stains, sometimes within the same run. The variety of available instrumentation offers unprecedented flexibility for laboratories to optimize their productivity and expand their menu of services.

## Advantages

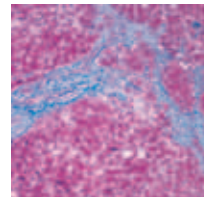
### Reagents

Special stains reagents are very diverse in their composition and chemistry. Acids, bases, solvents and toxic substances are commonly used in special stains techniques. Reagent preparation is time consuming and potentially hazardous, and the resulting reagents may not be of consistent quality. Many reagents must be mixed just before use from several stock solutions and may have relatively short working stability. A laboratory that offers a full menu of special stains must procure and store a large inventory of potentially hazardous materials in order to prepare the required reagents.

Automation can reduce or eliminate many of the concerns surrounding special stains reagents. Most automated special stains platforms come with ready-to-use reagents. Sometimes working reagents must be prepared prior to the run, but many instruments have the capability of automatically preparing working solutions onboard as needed. The use of ready-to-use reagents means the laboratory does not have to purchase and store the raw materials, spend time on reagent preparation or worry about consistent quality of the reagents. Hazards related to the storage of raw materials and reagent preparation are also reduced.

### Protocols

Special stains protocols are as diverse as the reagents used to perform them. Some protocols have as few as two or three steps, while others may have eight to 10. Reagent incubation times vary widely and may require incubations at elevated temperatures. Sometimes during manual staining, individual slides are examined under the microscope to evaluate the staining. The complication of the techniques makes it nearly impossible to successfully perform several staining procedures simultaneously. This combination of factors makes it a challenge to produce consistently reproducible results from day to



day and technician to technician. In addition, safe handling of hazardous waste is also a concern.

Automation of special stains can greatly improve a laboratory's ability to provide reproducible results in a timely fashion. Technicians can be much more productive when not encumbered with performing special stains manually. An automated special stains instrument can multitask effectively and perform many procedures simultaneously. Some platforms have the ability to heat either the staining chamber or even individual slides. Reagent waste is handled safely with a minimum of action required by the user other than to periodically empty the waste containers.

Reagent incubation times are tightly monitored by the instrument's software leading to highly reproducible results. Most platforms offer software flexibility that allows the user to optimize protocols and reagent incubation times to achieve the desired results.

### Considerations

Several factors should be considered when deciding to purchase an automated special stains platform.

- **Work load:** The slide capacity and throughput of the instrument should match the laboratory workload and test turnaround requirements.
- **Features:** Will the instrument perform only special stains, or are additional capabilities required for IHC or in situ hybridization?
- **Flexibility:** The flexibility of programming and reagent usage should match the expectations of users and the laboratory's menu of services.
- **Physical:** Bench space, power hookups and ventilation requirements are important to consider.
- **Ancillaries:** Additional supplies may be required for instrument operation, and this will affect the cost per test.
- **Vendor:** Availability of training, service and support are key considerations.

### Conclusion

Automation of special stains is rapidly becoming the norm in today's state-of-the-art laboratories. Instrumentation advances should continue to provide improved reproducibility of results, increased technician productivity and cost savings to laboratories that are willing to embrace technology when performing these classic techniques.



## Glossary

**Absorption:** The penetration and coloring of a tissue element without chemical changes or reactions.

**Acidic dye:** A negatively charged dye that easily stains acidophilic or eosinophilic elements, such as the cytoplasm, muscle and collagen.

**Acidophilic:** A substance or tissue element, usually basic in nature, that is easily stained with acid dyes.

**Aldehyde:** A reactive organic compound containing carbon, oxygen and hydrogen.

**Argentaffin:** A reaction in which silver impregnation and subsequent reduction result in visualization of a tissue element.

**Argyrophilic:** The ability to bind or be impregnated with silver ions.

**Artifact:** An element that is not normally present but that is produced by an external action.

**Background:** All nonspecific staining that results from procedural artifacts.

**Basic dye:** A positively charge dye that easily stains basophilic elements.

**Basophilic:** A substance or tissue element, usually acidic in nature, that is easily stained with basic dyes.

**Birefringence:** The splitting of a light wave into two waves that are refracted in different directions.

**Carbohydrates:** Compounds, including sugars, starches and cellulose, that contain only carbon, hydrogen and oxygen.

**Chromophilic:** Capable of being stained readily with dyes.

**Chromophore:** The specific chemical grouping that bestows the property of a color on a compound.

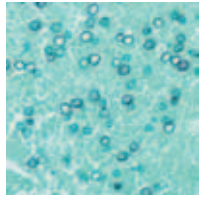
**Clearing:** The process of replacing alcohol with a reagent that can be mixed with paraffin.

**Counterstain:** A secondary stain that is applied to provide a visual contrast to the primary stain.

**Decolorization:** The removal of color from tissue.

**Dehydration:** The removal of water from tissue.

**Deparaffinization:** The removal of paraffin from a tissue section.



**Differentiation:** The removal of excess stain from a tissue section so that only the desired element remains stained.

**Eosinophilic:** A substance or tissue element, usually basic in nature, that is easily stained with acid dyes.

**Fixation:** The stabilization of protein.

**Hematein:** The oxidation product of hematoxylin; the active ingredient in hematoxylin solutions.

**Impregnation:** The deposition of metals on or around a tissue element of interest.

**Incubation:** To maintain tissue sections at optimal environmental reactions for a desired chemical reaction to occur.

**Lake:** The combination of a mordant with a dye.

**Mordant:** A reagent used to link a stain to a tissue.

**Oxidation:** A chemical reaction involving the removal of electrons from a molecule.

**Progressive staining:** Staining to the desired intensity and stopping the stain. No differentiation is required.

**Regressive staining:** Overstaining followed by decolorizing or differentiation.

**Reduction:** A chemical reaction involving the addition of electrons to a molecule.

**Ripening:** Oxidation.

## Index

**Acids** 14-15

**Acid-Fast Bacteria** 63-64

**AFB** (See Acid-Fast Bacteria)

***Afipia felis*** 65-66

**Alcian Blue** 53-56

**Alcian Yellow/Toluidine Blue** 66-67

**Alizarin Red S** 77-78

**Amyloid** 53

Congo red stain 57-59

***Aspergillus fumigatus*** 64-65

**Astrocytes** 82-84

**Automation** 86-87

**Bacteria** 9-10, 60

Acid-fast stain 63-64

*Afipia felis* 65-66

Alcian yellow/toluidine blue 66-67

*Bartonella henselae* 65-66

*Clostridium botulinum* 62-63

*Clostridium tetani* 62-63

Common methods 2

*Corynebacterium diphtheriae* 62-63

*Escherichia coli* 62-63

Giemsa stain 68

Gram stain 62-63

*Helicobacter pylori* 60, 65-68

Mycobacteria 60, 63-64

PAS-green stain 69

*Pseudomonas aeruginosa* 62-63

Rickettsia 68

Salmonella 62-63

*Shigella dysenteriae* 62-63

Spirochetes 60, 65-66

*Staphylococcus aureus* 62-63

Warthin-Starry stain 65-66

***Bartonella henselae*** 65-66

**Bases** 14-15

**Basement Membranes** 36-38

**Bielschowsky Method** 81-82

**Bile** 75-76

***Blastomyces dermatitidis*** 64-65

**Buffers** 14-15

**Calcium** 77

***Candida albicans*** 64-65

**Carbohydrates** 48-57

Alcian blue 53-56

Colloidal iron 56-57

Mucicarmine 52-53

PAS 49-52

**Cell** 5-6, 27

Staining methods 24-33

***Clostridium botulinum*** 62-63

***Clostridium tetani*** 62-63

***Coccidioides immitis*** 64-65

**Collagen** 34-46

**Colloidal Iron** 56-57

**Congo Red** 57-59

**Connective Tissue** 7-8, 34-40

Jones basement membrane stain 36-38

Reticulin nuclear fast red stain 35-36

Toluidine blue stain 39-40

Verhoeff-Van Gieson stain 38-39

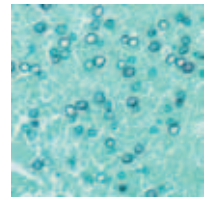
**Copper** 77-78

***Corynebacterium diphtheriae*** 62-63

**Cresyl Violet** 80-81

***Cryptococcus neoformans*** 64-65

**Cytoplasm** 6



- Giemsa stains** 31-33
  - H&E 24-28
- Dieterle** 2, 65
- DNA** 29-31
  - Feulgen stain 29-30
- Elastic Fibers** 38-39
- Eosin** 24-28
- Epithelial Tissue** 6
- Escherichia coli*** 62-63
- Feulgen Stain** 29-30
- Fixation** 17-21
  - Paraffin-embedded sections 18-20
  - Frozen sections 20-21
  - Smears 21
- Fungi** 11-12, 61
  - GMS stain 64-65
  - Aspergillus fumigatus* 64-65
  - Blastomyces dermatitidis* 64-65
  - Candida albicans* 64-65
  - Coccidioides immitis* 64-65
  - Common methods 2
  - Cryptococcus neoformans* 64-65
  - Histoplasma capsulatum* 64-65
  - Nocardia asteroides* 64-65
  - PAS-green stain 69
  - Pneumocystis carinii* 64-65
  - Sporothrix schenckii* 64-65
- Giemsa Stain** 2
  - Bone marrow 31-33
  - Helicobacter pylori* 68
  - Rickettsia 68
  - Toxoplasma gondii* 68
- Glial Cells** 82-83
- Glycogen** 48-52
- GMS** (See Grocott's Methenamine Silver)
- Gomori's Aldehyde Fuchsin** 73-74
- Gomori's Trichrome** 43
- Gram Stain** 62-63
- Grocott's Methenamine Silver** 64-65
- H&E** (See Hematoxylin & Eosin)
- Helicobacter pylori*** 60
  - Alcian yellow/toluidine blue 66-67
  - Giemsa stain 68
  - Warthin-Starry stain 65-66
- Hematein** 24-28
- Hematoxylin** 24-28
- Hematoxyling & Eosin** 24-28
- Hemosiderin** 72-73
- Histoplasma capsulatum*** 64-65
- Jones Basement Membrane Stain** 36-38
- Lipids** 46-47
  - Oil red O 46-47
  - Sudan black B 46-47
- Lipofuscin** 73-74
- Luxol Fast Blue** 83-84
- Masson's Trichrome** 41-42
- Mast Cells** 39-40
- Mayer's Mucicarmine** (See Mucicarmine)
- Melanin** 71-72
- Methyl Green-Pyronin Y Stain** 30-31
- Minerals** 76-78
  - Calcium 77
  - Copper 77-78
- Mucicarmine**
  - Microorganisms 2
  - Carbohydrates 52-53

## Special Stains

**Mucins** 45-46

**Mucopolysaccharides** 45-46

**Muscle Tissue** 8, 41-46

PTAH 44

Russel-Movat pentachrome 45-46

Trichrome stains 41-43

**Mycobacteria** 60

Acid-fast stain 63-64

**Myelin** 83-84

Luxol fast blue 83-84

**Nervous Tissue** 8, 80-85

Astrocytes 82-83

Bielschowsky method 81-82

Cresyl violet stain 80-81

Glial cells 82-83

Myelin 83-85

Neurons 80-82

Nissl substance 80-81

PTAH 83

**Neurons** 80-82

**Nissl Substance** 80-81

***Nocardia asteroides*** 64-65

**Nucleic Acids** 29-31

Feulgen stain 29-30

Methyl green-pyronin Y stain 30-31

**Nucleus** 6

Staining methods 27-37

**Oil Red O** 46-47

**Oxidation** 14

**PAS** (See Periodic Acid-Schiff)

**PAS with Diastase** 51-52

**PAS-Green Stain** 69

**Pathogens** 8-12

Common methods 2

**Periodic Acid-Schiff**

Microorganisms 2

Carbohydrates 49-52

Fungi 69

**Perl's Method** 72-73

**pH** 14-15

**Phosphotungstic Acid-Hematoxylin**

Muscle 44

Astrocytes 82-84

**Pigments** 71-76

Bile 75-76

Hemosiderin 72-73

Lipofuscin 73-74

Melanin 71-72

Urates 74-75

***Pneumocystis carinii*** 64-65

**Polychromatic Stains** (See also Giemsa Stain)

31-33

**Protozoans** 12, 61

Common methods 2

Giemsa stain 68

***Pseudomonas aeruginosa*** 62-63

**PTAH** (See Phosphotungstic Acid-Hematoxylin)

**RNA** 29-31

Methyl green-pyronin Y stain 30-31

**Reduction** 14

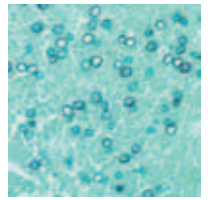
**Reticular Fibers** 35-36

**Reticulin Nuclear Fast Red Stain** 35-36

**Rhodanine Method** 78

**Rickettsia** 68

**Romanowsky-Giemsa Stain** (See Giemsa Stain)



**Russel-Movat Pentachrome** 45-46

**Salmonella** 62-63

**Specimen Processing** 21-22

***Shigella dysenteriae*** 62-63

**Spirochetes** 11, 60

Common methods 2

Warthin-Starry stain 65-66

***Sporothrix schenckii*** 64-65

***Staphylococcus aureus*** 62-63

**Steiner & Steiner** 2, 65

**Sudan Black B** 46-47

**Tissue**

Overview 6-8

Fixation & Processing 17-23

**Toluidine Blue** 39-40

***Toxoplasma gondii*** 68

**Trichrome Stains** 41-43

**Urates** 74

**VVG** (See Verhoeff-Van Gieson Stain)

**Verhoeff-Van Gieson Stain** 43-44

**Warthin-Starry**

*Afpia felis* 65-66

*Bartonella henselae* 65-66

*Helicobacter pylori* 65-66

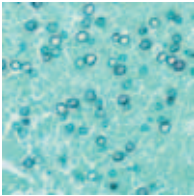
Melanin 71-72

Spirochetes 65-66





Notes



A series of horizontal lines for writing notes, starting below a dotted line and extending to the bottom of the page.



For further information please contact your local DakoCytomation office:

**Australia**  
Tel. 2 9316 4633  
Fax 2 9316 4773

**Austria**  
Tel. 0800 0800 7153  
Fax 0800 0800 7154

**Belgium**  
Tel. 016 38 72 20  
Fax 016 38 72 21

**Canada**  
Tel. 905 858 8510  
Fax 905 858 8801

**Czech Republic**  
Tel. 420 541 423 710  
Fax 420 541 423 711

**Denmark**  
Tel. 44 85 97 56  
Fax 44 85 84 29

**France**  
Tel. 1 30 50 00 50  
Fax 1 30 50 00 11

**Germany**  
Tel. 040 69 69 470  
Fax 040 69 52 741

**Ireland**  
Tel. 1800 333256  
Fax 91 763674

**Italy**  
Tel. 02 58 078 1  
Fax 02 58 078 292

**Japan**  
Tel. 075 211 3655  
Fax 075 211 1755

**The Netherlands**  
Tel. 020 42 11 100  
Fax 020 42 11 101

**Norway**  
Tel. 23 14 05 40  
Fax 23 14 05 42

**Poland**  
Tel. 058-661 1879  
Fax 058-661 3390

**Spain**  
Tel. 93 499 05 06  
Fax 93 499 02 08

**Sweden**  
Tel. 08 556 20 600  
Fax 08 556 20 619

**Switzerland**  
Tel. 041 760 11 66  
Fax 041 760 11 77

**United Kingdom**  
Tel. (0)1 353 66 99 11  
Fax (0)1 353 66 89 89

**Technical Support**  
Tel. (0)1 353 66 99 65

**United States of America**  
Tel. 805 566 6655  
Fax 805 566 6688

**Customer Service**  
Tel. 800 235 5763

**Technical Support**  
Tel. 800 424 0021

**Flow Instrumentation**  
Tel. 800 822 9902  
Fax 970 226 0107

Corporate Headquarters: Denmark • Tel. +45 44 85 95 00 • Fax +45 44 85 95 95  
[www.dakocytomation.com](http://www.dakocytomation.com) • Distributors in more than 50 countries